

Search PubMed for platelet rich plasma [Advanced Search](#)

About Entrez
Text Version

[Limits](#) [Preview/Index](#) [History](#) [Clipboard](#) [Details](#)


Display Show Sort By Send to

All: 76 Review: 12

Items 1 - 76 of 76

One page.

Entrez PubMed

Overview
Help | FAQ
Tutorials
New/Noteworthy 
E-Utilities

PubMed Services

Journals Database
MeSH Database
Single Citation
Matcher
Batch Citation Matcher
Clinical Queries
Special Queries
LinkOut
My NCBI

Related Resources

Order Documents
NLM Mobile
NLM Catalog
NLM Gateway
TOXNET
Consumer Health
Clinical Alerts
ClinicalTrials.gov
PubMed Central

1: [Med Hypotheses](#). 2009 Mar 24. [Epub ahead of print]

[Related Articles,](#)
[Links](#)



Comment on "Platelet-Rich Plasma as a novel therapeutic agent in osteomyelitis"

[Jia W](#), [Zhang C](#).

Department of Orthopedic Surgery, Shanghai Sixth People's Hospital, Shanghai Jiaotong University, No. 600 Yishan Road, 200233, Shanghai, PR China. Tel.: +86 02164369181x8062; fax: +86 02164369181.

Publication Types:

- [LETTER](#)

PMID: 19321269 [PubMed - as supplied by publisher]

2: [Plast Reconstr Surg](#). 2009 Mar;123(3):1135-6; author reply 1136-7.

[Related Articles,](#)
[Links](#)



Platelet-rich plasma: the importance of platelet separation and concentration.

[Kakudo N](#), [Kushida S](#), [Kusumoto K](#).

Publication Types:

- [Letter](#)

PMID: 19319101 [PubMed - in process]

3: [Knee Surg Sports Traumatol Arthrosc](#). 2009 Mar 14.
[Epub ahead of print]

[Related Articles,](#)
[Links](#)



Anatomic ACL reconstruction: does the platelet-rich plasma accelerate tendon healing?

[Silva A](#), [Sampaio R](#).

Military Hospital D. Pedro V, Avenida da Boavista, 4050-113, Porto, Portugal,

Recently, the use of hamstring tendons in anterior cruciate ligament repair has been increasing. However, tendon-to-bone healing occurs slowly, which can be a problem to an early return to sport activities. The use of growth factors from platelets seems to improve tissue healing. We enrolled 40 patients in a prospective study that were submitted to an anatomic reconstruction of the anterior cruciate ligament. Patients were sequentially enrolled into four groups: group A without platelet-rich plasma (PRP); group B with PRP in femoral tunnels at the end of surgery; group C with PRP in femoral tunnels at the end of surgery and intra-articular at 2- and 4 weeks after surgery; group D with PRP activated with thrombin in the femoral tunnels. All patients underwent magnetic resonance imaging of the knee 3 months after surgery to evaluate the signal intensity of the fibrous interzone (FIZ) in the femoral tunnels. We did not find any difference among the groups when comparing the signal intensity of the FIZ on magnetic resonance imaging.

PMID: 19288080 [PubMed - as supplied by publisher]

-
- 4: [Am J Sports Med.](#) 2009 Mar 12. [Epub ahead of print]

[Related Articles,](#)
[Links](#)



Use of Autologous Platelet-rich Plasma to Treat Muscle Strain Injuries.

[Hammond JW](#), [Hinton RY](#), [Curl LA](#), [Muriel JM](#), [Lovering RM](#).

Union Memorial Hospital.

BACKGROUND: Standard nonoperative therapy for acute muscle strains usually involves short-term rest, ice, and nonsteroidal anti-inflammatory medications, but there is no clear consensus on how to accelerate recovery. **HYPOTHESIS:** Local delivery of platelet-rich plasma to injured muscles hastens recovery of function. **STUDY DESIGN:** Controlled laboratory study. **METHODS:** In vivo, the tibialis anterior muscles of anesthetized Sprague-Dawley rats were injured by a single (large strain) lengthening contraction or multiple (small strain) lengthening contractions, both of which resulted in a significant injury. The tibialis anterior either was injected with platelet-rich plasma, was injected with platelet-poor plasma as a sham treatment, or received no treatment. **RESULTS:** Both injury protocols yielded a similar loss of force. The platelet-rich plasma only had a beneficial effect at 1 time point after the single contraction injury protocol. However, platelet-rich plasma had a beneficial effect at 2 time points after the multiple contraction injury protocol and resulted in a faster recovery time to full contractile function. The sham injections had no effect compared with no treatment. **CONCLUSION:** Local delivery of platelet-rich plasma can shorten recovery time after a muscle strain injury in a small-animal model. Recovery of muscle from the high-repetition protocol has already been shown to require myogenesis, whereas recovery from a single strain does not. This difference in mechanism of recovery may explain why platelet-rich plasma was more effective in the high-repetition protocol, because platelet-rich plasma is rich in growth factors that can stimulate myogenesis. **CLINICAL RELEVANCE:** Because autologous blood products are safe, platelet-rich plasma may be a useful product in clinical treatment of muscle injuries.

PMID: 19282509 [PubMed - as supplied by publisher]

-
- 5: [Am J Sports Med.](#) 2009 Mar 11. [Epub ahead of print]

[Related Articles,](#)
[Links](#)



In Vitro Model to Study Chondrogenic Differentiation in Tendinopathy.

[de Mos M](#), [Koevoet W](#), [van Schie HT](#), [Kops N](#), [Jahr H](#), [Verhaar JA](#), [van Osch GJ](#).

Erasmus MC, University Medical Centre Rotterdam.

BACKGROUND: Treatment of midportion Achilles tendinopathy is hampered by limited knowledge of the pathophysiology. **HYPOTHESIS:** Chondrogenic differentiation of tendon cells might take place in midportion Achilles tendinopathy and could be used as a target for drug treatment. An in vitro model for chondrogenic differentiation would be useful to evaluate existing and future treatment opportunities. **STUDY DESIGN:** Descriptive and controlled laboratory study. **METHODS:** Perioperatively harvested tissue from human midportion Achilles tendinotic lesions and healthy Achilles tendons was analyzed by microscopy and real-time reverse transcription polymerase chain reaction. In vitro chondrogenic differentiation of tendon explants was induced using transforming-growth-factor beta. This model was modulated by removing the chondrogenic stimulus or adding triamcinolone or platelet-rich plasma. **RESULTS:** Midportion Achilles tendinotic lesions had increased glycosaminoglycan staining and more rounded cell nuclei. Chondrogenic markers (sex-determining region Y)-box9, aggrecan, collagen 2, and RUNT-related transcription factor 2 were upregulated, but collagen 10 was not. Nondegenerative tendon explants cultured on chondrogenic medium had higher expression of aggrecan, collagen 2, and collagen 10 but not (sex-determining region Y)-box9 and RUNT-related transcription factor 2. Removing the chondrogenic stimulus decreased expression of aggrecan, collagen 2, and collagen 10. Both triamcinolone and platelet-rich plasma influenced the chondrogenic gene expression pattern in the in vitro model. **CONCLUSION:** Chondrogenic differentiation is present in midportion Achilles tendinopathy. An in vitro model to study this chondrogenic differentiation was developed. **CLINICAL RELEVANCE:** This model can be used to investigate chondrogenic differentiation as a possible target for drug treatment, contributing to the development of more successful mechanism-based treatment opportunities.

PMID: 19279223 [PubMed - as supplied by publisher]

6: [Acta Biomed.](#) 2008 Dec;79(3):223-6.

[Related Articles,](#)
[Links](#)



**The "Cascade" membrane: a new PRP device for tendon ruptures.
Description and case report on rotator cuff tendon.**

[Maniscalco P](#), [Gambera D](#), [Lunati A](#), [Vox G](#), [Fossombroni V](#), [Beretta R](#), [Crainz E](#).

Unit of Orthopedics, University of Siena, Siena, Italy.

Rotator cuff tears are common soft-tissue injuries that often require surgical treatment. Initial efforts to better tendon healing centered on improving the strength of repair. More recent studies have focused on abiologic enhancement of the healing process. Platelet rich plasma (PRP) is a fraction of plasma that has been isolated and used to enhance regeneration in bone and soft tissues. The healing potential of PRP has been attributed to the release of multiple growth factors from the highly concentrated platelets. The "Cascade" membrane is a thin layer of autologous fibrine that is very rich in platelets and is obtained by high speed centrifugation of a small quantity of PRP. The Authors present the case of C.U., a right-handed 53 year-old male that came to our attention complaining of severe right shoulder pain and ROM reduction. The MRI showed a thick tear of the sovraspinatus tendon with retraction of the muscle. The patient underwent surgical repair with arthroscopy and mini-open approach with acromionplasty, subacromial decompression, cuff repair by trans-bone suture and application of the "Cascade" membrane (A.T. Grade Milano, Italy) that was sutured side-to-side to close the 10 mm tear. A standard rehabilitation protocol for rotator cuff tears was performed. A MRI 6 months after surgical repair showed the complete integrity of the cuff under the membrane. Currently no widely accepted treatment for massive, irreparable rotator cuff tears is available. Allograft reconstruction to span the remaining defect in massive rotator cuff tears will lead to increase functional results; we believe that further studies are needed to describe and evaluate its potential in tendon healing; multiple MRI studies will demonstrate healing of the tendon with the graft.

Publication Types:

- [Case Reports](#)

PMID: 19260383 [PubMed - indexed for MEDLINE]

□ 7: [Orv Hetil.](#) 2009 Mar 15;150(11):517-22.

[Related Articles,](#)
[Links](#)

[Effect of combined therapeutical methods on healing of intrabony defects in regenerative periodontal surgery.]

[Article in Hungarian]

[Dori F.](#)

Semmelweis Egyetem Klinikai Orvostudományok Doktori Iskola Budapest Szentkirályi utca 47. 1088.

Several methods are available to enhance the healing and regeneration of periodontal tissues after surgical therapy of intrabony defects. The main indications for the use of combined regenerative procedures are the extent and morphology of the osseous lesions. The six studies of the present dissertation focused on the clinical effect of different barrier techniques, bone substitutes, enamel matrix derivatives and a growth factors containing adjuvant used in various combinations on the healing of severe periodontal intrabony impairments. Synthetic, xenogenetic and autologous materials were used in these randomized clinical studies. Mechanical barriers (polytetrafluoroethylene and collagen membranes) for GTR, biological barriers/enamel matrix proteins (EMD), synthetic (beta-TCP) and xenogeneic (NBM) bone grafts and autologous platelet-rich plasma (PRP) were combined in the test and control groups of the trials. The main clinical variable was the clinical attachment level (CAL) and the subsidiary one was the probing pocket depth (PPD), estimated at baseline and after one year. The summation of the results after the statistical analysis takes cognizance of the followings: a) Each of the eleven regenerative methods evaluated (ten combined procedures) leads to significant CAL gain and PPD decrease. b) Using beta-TCP or NBM with EMD or with PRP + GTR and GTR's, the difference between the parameters of the test and control groups were not statistically significant. c) It was confirmed in four studies that the addition of PRP to graft materials has not increased significantly the positive outcomes independent of the type of barrier or graft. d) Adding platelet-rich plasma to natural bone mineral, no benefit was observed from the point of view of the clinical variables. e) The polypeptide proteins of the platelet-rich plasma do not enhance the clinical regenerative effect of enamel matrix proteins. In conclusion, the option of the periodontal surgeons between these methods depends mainly on the defect morphology, the patient's approach to the different types of materials, the medical concept of the physician, the technical possibilities and the clinical experience of the periodontist.

Publication Types:

- [English Abstract](#)

PMID: 19258248 [PubMed - in process]

□ 8: [Cell Prolif.](#) 2009 Apr;42(2):162-70. Epub 2009 Feb 24.

[Related Articles,](#)
[Links](#)



Fibroblastic response to treatment with different preparations rich in growth factors.

[Anitua E.](#), [Sánchez M.](#), [Zalduendo MM.](#), [de la Fuente M.](#), [Prado R.](#), [Orive G.](#), [Andía I.](#)

Biotechnology Institute, BTI IMASD, Vitoria-Gasteiz, Spain.

OBJECTIVES: Preparations rich in growth factors (PRGF) release them plus bioactive proteins at localized sites, with the aim of triggering healing and regenerative processes. The prevailing paradigm suggests that their influence on proliferation, angiogenesis and the extracellular matrix synthesis is minimal. However, variations in their composition and impact on different cell phenotypes have not been examined. **MATERIALS AND METHODS:** Sixteen fibroblast cultures obtained from three different anatomical sites (skin, synovium and tendon) of 16 donors were exposed to the molecular pool released from PRGF scaffolds, with increasing amounts of platelets. We evaluated cell proliferation, secretion of angiogenic growth factors (VEGF and HGF), synthesis of type I collagen and hyaluronic acid (HA), considering platelet dose and anatomical origin of the cells. Activity of transforming growth factor-beta (TGF-beta) in type I procollagen and HA synthesis was examined by adding exogenous TGF-beta to plasma preparations. **RESULTS:** All plasma preparations induced a significant proliferative response compared to non-stimulated cells ($P < 0.05$). Maximum proliferation rate was obtained with PRGF with 2-fold or 4-fold platelet concentration. Exposure to PRGF stimulated VEGF synthesis exclusively in tendon cells ($P < 0.05$), which also exhibited a different pattern of HGF production ($P < 0.05$). PRGF enhanced HA synthesis ($P < 0.05$), but did not alter collagen I production. Platelet-secreted TGF-beta may be involved in HA, but not in type I procollagen synthesis. **CONCLUSIONS:** Optimizing composition and use of platelet-rich products is crucial to enhancing the therapeutic potential of this technology. Our data show that the biological effects of PRGF may depend on concentration of platelets and on the anatomical source of the cells.

Publication Types:

- [Research Support, Non-U.S. Gov't](#)

PMID: 19250293 [PubMed - in process]

9: [Am J Vet Res.](#) 2009 Feb;70(2):277-82.

[Related Articles,
Links](#)



Effects of platelet-rich plasma on the repair of wounds on the distal aspect of the forelimb in horses.

[Monteiro SO](#), [Lepage OM](#), [Theoret CL](#).

Ecole Nationale Vétérinaire de Lyon, Département Hippique, Marcy L'Etoile, F-69280, France.

OBJECTIVE: To evaluate the effect of platelet-rich plasma on wounds on the distal aspect of the forelimb in horses. **ANIMALS:** 6 mixed-breed 10- to 15-year-old mares. **PROCEDURES:** 3 wounds were created on metacarpal regions in each of 6 horses ($n = 36$ wounds total). Eighteen wounds were treated with platelet-rich plasma and bandaged, whereas 18 control wounds were similarly bandaged with no prior topical treatment. Decrease in wound surface area and the required number of excisions of exuberant granulation tissue were recorded until complete healing. Tissue specimens were taken from wounds at 1 week for histologic examination and measurement of transforming growth factor-beta1 concentrations and at closure for histologic examination, biomechanical evaluation, and measurement of collagen type I and type III mRNA. **RESULTS:** Platelet-rich plasma favored excessive development of granulation tissue and significantly slowed wound healing at 1, 2, and 3 weeks after surgery. Transforming growth factor-beta1 had a 1.6-fold higher concentration in treated wounds, compared with untreated wounds. Histologic, biomechanical, and gene expression data did not differ significantly between treated and control wounds. **CONCLUSIONS AND CLINICAL RELEVANCE:** Topical application of autologous platelet-rich plasma did not accelerate or improve the quality of

repair of small granulating wounds on limbs of horses. This treatment may better suit wounds with massive tissue loss or, alternatively, chronic wounds that would benefit from a fresh source of mediators to accelerate the healing process.

Publication Types:

- [Research Support, Non-U.S. Gov't](#)

PMID: 19231962 [PubMed - indexed for MEDLINE]

10: [Tissue Eng Part C Methods](#), 2009 Feb 20. [Epub ahead of print]

[Related Articles,](#)
[Links](#)



Application of Platelet-rich Plasma to Fat Grafting during Plastic Surgical procedures: Clinical and In Vitro evaluation.

[Cervelli V](#), [Gentile P](#), [Scioli MG](#), [Grimaldi M](#), [Spagnoli LG](#), [Orlandi A](#).

University of TOR VERGATA, Plastic and reconstructive surgery, Rome, Italy;
valeriocervelli@libero.it.

The clinical use of platelet-rich plasma (PRP) for a wide variety of applications has been reported, most prevalently in the problematic wound, maxillofacial, hemifacial atrophy, Romberg Syndrome, diabetic foot ulcers and spine literature. To our knowledge, PRP has never been described to favour fat grafting for in vivo tissue-engi notneering applications. The authors describe the preparation of PRP and its use in a series of 43 patients underwent fat grafting during plastic, and maxillofacial surgery (n=25) and lower extremity chronic ulcers reconstructive surgery (n=18). PRP mixed with fat grafting was used in 76% patients affected by multiple facial disease and in 88.9% patients affected by chronic ulcers. PRP injection alone was used in remaining patients. The authors observed that after a 7.1 and 9.7-week (average) course of twice-daily wound treatment with PRP suspended on a collagen base, 61.1 and 88.9% of chronic lower extremity ulcers underwent to 100% reepithelialisation compared with 40 and 60% of controls (n=10) treated with ialuronic acid and collagen medication. In patients treated with reconstructing three-dimensional projection of face by fat grafting and PRP, we observed a 69% maintenance of contour restoring and three-dimensional volume after 1 year compared to only 30% of controls (n=10) treated with fat grafting alone. In vitro, PRP induced a significant increase of adipose-tissue-derived stem cells number compared to control cultures. These results clearly documented that PRP favour maintenance and function of fat graft in patients underwent plastic reconstructive surgery, possibly by stimulating adipose-tissue-derived stem cells proliferation.

PMID: 19231923 [PubMed - as supplied by publisher]

11: [J Periodontol](#), 2009 Jan;80(1):62-71.

[Related Articles,](#)
[Links](#)



Clinical effectiveness of autologous platelet-rich plasma and Peptide-enhanced bone graft in the treatment of intrabony defects.

[Pradeep AR](#), [Shetty SK](#), [Garg G](#), [Pai S](#).

Department of Periodontics, Government Dental College and Research Institute, Bangalore, Karnataka, India.

BACKGROUND: The goal of periodontal therapy has always been the regeneration of lost attachment apparatus. The use of platelet-rich plasma (PRP) plus anorganic bovine-derived

matrix and peptide 15 (ABM/P-15) for periodontal regenerative therapy offers a potentially useful modality for treating periodontal osseous defects. However, it is unknown whether a combination of these materials enhances the outcome of periodontal regenerative therapy. Therefore, this study was carried out to compare the effectiveness of the two regenerative techniques (autologous PRP plus ABM/P-15 versus autologous PRP) in treating intrabony defects in humans by analyzing the clinical and radiologic parameters. **METHODS:** Using a split-mouth design, 28 intrabony defects were treated with autologous PRP (control) or a combination of autologous PRP and ABM/P-15 (test). Clinical parameters such as plaque index, sulcus bleeding index, probing depth, attachment level, and gingival marginal level were recorded at baseline and 9 months postoperatively. Hard tissue measurements such as defect fill, defect resolution, and change in alveolar crest height were also recorded using spiral computed tomography (CT). **RESULTS:** A statistically significant difference was observed in all clinical parameters in the test group compared to the control group. Furthermore, spiral CT images revealed significantly greater bone fill in the test group. **CONCLUSIONS:** A combination of PRP plus ABM/P-15 was more effective than PRP alone in the treatment of intrabony defects. Further studies using a larger sample size are necessary to confirm the results of the present study.

PMID: 19228091 [PubMed - in process]

12: [Plast Reconstr Surg.](#) 2009 Feb;123(2 Suppl):56S-64S.

[Related Articles, Links](#)



Adipose stromal cells and platelet-rich plasma therapies synergistically increase revascularization during wound healing.

[Blanton MW](#), [Hadad I](#), [Johnstone BH](#), [Mund JA](#), [Rogers PI](#), [Eppley BL](#), [March KL](#).

Department of Surgery, Division of Plastic Surgery, Indiana University School of Medicine, Indianapolis, Indiana 46202, USA. mwblanto@iupui.edu

BACKGROUND: The authors examined the efficacy of adipose stem cells, when supplied either alone or in platelet-rich fibrin gels, to improve wound healing. **METHODS:** A porcine full-thickness wound model was used to compare six topical treatments: platelet-poor plasma; platelet-rich plasma; autologous adipose stem cells plus platelet-poor plasma; autologous adipose stem cells plus platelet-rich plasma; allogeneic adipose stem cells containing green fluorescent protein plus platelet-poor plasma; and saline (control). One week after isolation, adipose stem cells were applied to full-thickness wounds on the paraspinal and thoracic regions of three pigs (44 wounds per pig; each treatment was applied to eight separate wounds). Each wound was monitored over 21 days for closure, cosmesis, and histopathology. **RESULTS:** There was no significant difference in the reepithelialization rate, but treatments containing adipose stem cells demonstrated increased microvessel densities (31.75 +/- 5.73 vessels/cm² versus 7.93 +/- 3.61 vessels/cm²) compared with groups without adipose stem cells. Wound cosmesis was improved in the adipose stem cell plus platelet-rich plasma group compared with other treatment groups (p < 0.05). Vascular endothelial growth factor levels detected in matrices containing adipose stem cells were approximately 7-fold higher compared with platelet-rich plasma or platelet-poor plasma (p < 0.05). Localization of transgenic green fluorescent protein plus adipose stem cells indicated incorporation near neovasculature. **CONCLUSIONS:** In normal healing wounds, adipose stem cells appear to enhance the healing process only when provided in a fibrin gel vehicle containing a number of complementary wound-healing trophic factors. Perivascular adipose stem cell localization suggests a function in enhancing blood supply through providing physical and paracrine support to newly forming vessels.

Publication Types:

- [Research Support, N.I.H., Extramural](#)
- [Research Support, Non-U.S. Gov't](#)

□ 13: [J Knee Surg.](#) 2009 Jan;22(1):36-44.

[Related Articles,](#)
[Links](#)

Biological approaches for cartilage repair.

[Gobbi A, Bathan L.](#)

Orthopaedic Arthroscopic Surgery International Bioresearch Foundation, Milan, Italy.

The social impact of bone and cartilage pathologies entails high costs in terms of therapeutic treatments and loss of income. As a result, the current research trend includes preventive interventions and therapeutic solutions that can lead to an enhancement of tissue regeneration and the reduction of degenerative mechanisms. Many options have been made available to address problems regarding cartilage damage, each with its own advantages and disadvantages. Several studies are currently in progress to clarify some of the questions that remain unanswered about the long-term durability of these procedures and the possible modifications that can be made to achieve better results. Biotechnology is progressing at a rapid pace that allows the introductions of several products for clinical application; however, randomized, prospective studies for these innovations should be conducted to validate the safety and efficacy of cartilage regeneration.

Publication Types:

- [Review](#)

PMID: 19216352 [PubMed - indexed for MEDLINE]

□ 14: [J Periodontal Res.](#) 2009 Apr;44(2):258-65. Epub 2009 Feb 6.

[Related Articles,](#)
[Links](#)



The effect of platelet-rich plasma on osteoblast and periodontal ligament cell migration, proliferation and differentiation.

[Creepier E, Lichanska AM, Marshall RI, Seymour GJ, Ivanovski S.](#)

School of Dentistry, The University of Queensland, Queensland, Australia.

BACKGROUND AND OBJECTIVE: Platelet-rich plasma is used to deliver growth factors, in a safe and convenient manner, for enhancing bone and periodontal regeneration. However, conflicting reports regarding its effectiveness suggest that further study of the relevant cellular mechanisms is required. The aim of this study was to investigate the in vitro effect of platelet-rich plasma on osteoblasts and periodontal ligament cell function. **MATERIAL AND METHODS:** Various concentrations of platelet-rich plasma (100, 50, 20 and 10%) and platelet-poor plasma, obtained from human donors, were applied to primary cultures of human osteoblasts and periodontal ligament cells. [(3)H]-Thymidine incorporation, crystal violet staining and MTT assays were utilized to assess DNA synthesis and proliferation. Migration was determined by assessing the cell response to a concentration gradient, while differentiation was assessed using Alazarin Red staining. **RESULTS:** Platelet-rich plasma and platelet-poor plasma had stimulatory effects on the migration of both human osteoblasts and periodontal ligament cells. At 24 h, DNA synthesis was suppressed by the application of the various concentrations of platelet-rich plasma, but over a 5-d period, a beneficial effect on proliferation was observed, especially in response to 50% platelet-rich plasma. Platelet-poor plasma resulted in the greatest enhancement of cellular proliferation for both cell types. At a concentration of 50%, platelet-rich plasma and platelet-poor plasma facilitated differentiation of both cell types. **CONCLUSION:** Platelet-rich plasma can exert a positive effect on osteoblast and periodontal ligament cell function,

but this effect is concentration specific with maximal concentrations not necessarily resulting in optimal outcomes. Platelet-poor plasma also appears to have the ability to promote wound healing-associated cell function.

Publication Types:

- [Research Support, Non-U.S. Gov't](#)

PMID: 19210334 [PubMed - in process]

□ 15: [Int Orthop](#). 2009 Feb 11. [Epub ahead of print]

[Related Articles,](#)
[Links](#)



Immunohistochemical study of angiogenesis after local administration of platelet-rich plasma in a patellar tendon defect.

[Lyras D](#), [Kazakos K](#), [Verettas D](#), [Polychronidis A](#), [Simopoulos C](#), [Botaitis S](#), [Agrogiannis G](#), [Kokka A](#), [Patsouris E](#).

Orthopaedic Clinic, Democritus University of Thrace, Alexandroupolis, Greece, dimitrislyras@yahoo.gr.

A full thickness defect was made in the central portion of the patellar tendon of 48 New Zealand white rabbits. Platelet-rich plasma (PRP) gel was then applied and filled the tendon defect. The same procedure was performed in the control group, without the application of PRP. Animals were sacrificed after one, two, three, and four weeks. Histological and immunohistochemical analyses using a monoclonal antibody against CD31 were performed. The histological examination showed a superior healing process in the PRP group compared with the control group. Especially in the third week, the tissue formed in the PRP group was more mature and dense with less elastic fibres remaining. Neovascularisation was significantly higher in the PRP group during the first two weeks and significantly lower in the third and fourth weeks ($p < 0.0001$). Histological examination and study of angiogenesis showed that the application of PRP enhances and accelerates the tendon healing process.

PMID: 19205700 [PubMed - as supplied by publisher]

□ 16: [Tissue Eng Part A](#). 2009 Feb 3. [Epub ahead of print]

[Related Articles,](#)
[Links](#)



Bone Regeneration with Autologous Plasma, Bone Marrow Stromal Cells, and Porous beta-Tricalcium Phosphate in Nonhuman Primates.

[Torigoe I](#), [Sotome S](#), [Tsuchiya A](#), [Yoshii T](#), [Maehara H](#), [Sugata Y](#), [Ichinose S](#), [Shinomiya K](#), [Okawa A](#).

1 Section of Orthopaedic and Spinal Surgery, Graduate School, Tokyo Medical and Dental University, Tokyo, Japan., 2 Section of Regenerative Therapeutics for Spine and Spinal Cord, Graduate School, Tokyo Medical and Dental University, Tokyo, Japan., 3 Global Center of Excellence (GCOE) Program; International Research Center for Molecular Science in Tooth and Bone Diseases, Tokyo Medical and Dental University, Tokyo, Japan., 4 Instrumental Analysis Research Center, Tokyo Medical and Dental University, Tokyo, Japan., 5 Hard Tissue Genome Research Center, Tokyo Medical and Dental University, Tokyo, Japan., 6 Core to Core Program for Advanced Bone and Joint Science, Tokyo Medical and Dental University, Tokyo, Japan.

To potentiate the bone formation capability of bone marrow stromal cell (BMSC)/beta-tricalcium phosphate (beta-TCP) constructs, we devised an autologous plasma-based

construct. We tested its effectiveness and investigated the effects of its components on a monkey ectopic bone formation model. The autologous plasma (platelet-rich plasma, PRP, or platelet-poor plasma, PPP)/BMSC/beta-TCP construct (R group or P group) showed significantly more bone formation at 3 and 6 weeks after implantation than a conventional BMSC/beta-TCP construct using a culture medium (M group). There was no significant difference between the P and R groups. Moreover, the P group constructs with a 10-fold lower cell concentration yielded equivalent bone formation to the M group at 5 weeks after implantation. To elucidate the effect of fibrin and serum contained in the plasma, five constructs were prepared using the following cell vehicles: autologous serum+fibrinogen (0, 1, 4, or 16 mg/mL) or phosphate-buffered saline+fibrinogen (4 mg/mL). The serum+fibrinogen (4 mg/mL, physiological concentration of monkeys) construct showed the most abundant bone formation at 3 weeks after implantation, though at 5 weeks no statistical difference existed among the groups. Autologous plasma efficiently promoted osteogenesis of BMSCs/porous beta-TCP constructs, and both fibrin and serum proved to play significant roles in the mechanism.

PMID: 19191499 [PubMed - as supplied by publisher]

17: [Trends Biotechnol.](#) 2009 Mar;27(3):158-67. Epub 2009 Jan 31.

[Related Articles,](#)
[Links](#)



Classification of platelet concentrates: from pure platelet-rich plasma (P-PRP) to leucocyte- and platelet-rich fibrin (L-PRF).

[Dohan Ehrenfest DM](#), [Rasmusson L](#), [Albrektsson T](#).

Department of Biomaterials, Institute of Clinical Sciences, The Sahlgrenska Academy at University of Gothenburg, Sweden. LoB5@mac.com

The topical use of platelet concentrates is recent and its efficiency remains controversial. Several techniques for platelet concentrates are available; however, their applications have been confusing because each method leads to a different product with different biology and potential uses. Here, we present classification of the different platelet concentrates into four categories, depending on their leucocyte and fibrin content: pure platelet-rich plasma (P-PRP), such as cell separator PRP, Vivostat PRF or Anitua's PRGF; leucocyte- and platelet-rich plasma (L-PRP), such as Curasan, Regen, Plateletex, SmartPreP, PCCS, Magellan or GPS PRP; pure platelet-rich fibrin (P-PRF), such as Fibrinet; and leucocyte- and platelet-rich fibrin (L-PRF), such as Choukroun's PRF. This classification should help to elucidate successes and failures that have occurred so far, as well as providing an objective approach for the further development of these techniques.

Publication Types:

- [Research Support, Non-U.S. Gov't](#)

PMID: 19187989 [PubMed - in process]

18: [Chin Med J \(Engl\)](#). 2009 Jan 5;122(1):83-7.

[Related Articles,](#)
[Links](#)



Preliminary separation of the growth factors in platelet-rich plasma: effects on the proliferation of human marrow-derived mesenchymal stem cells.

[Huang Q](#), [Wang YD](#), [Wu T](#), [Jiang S](#), [Hu YL](#), [Pei GX](#).

Department of Orthopedics and Traumatology, Nanfang Hospital, Southern Medical University, Guangdong, China.

BACKGROUND: Platelet-rich plasma (PRP) as a storage vehicle of growth factors has been successfully used in clinical applications, but in most cases the platelets were autologous. However, the large volume of blood withdrawn has detrimental effects on patients with anemia or poor general health. To overcome these limitations, this study was designed to separate the growth factors in homologous platelet-rich plasma. **METHODS:** The gel chromatography with Superdex-75 column was applied to separate PRP supernatants into 4 major fractions. Then the four fractions were vacuumed freeze-dried and re-dissolved in phosphate buffered saline. Proteins concentrations in PRP and in four fractions were detected by bicinchoninic acid protein assay; platelet derived growth factor-AB (PDGF-AB) and transforming growth factor beta1 (TGF-beta1) levels were determined by sandwich enzyme-linked immunosorbent assays. The effects of fractions on the proliferation of human marrow-derived mesenchymal stem cells (MSCs) were determined by 3-(4, 5-dimethylthiazol-2-yl)-2, 5-diphenyltetrazolium bromide (MTT) assay. **RESULTS:** PRP supernatants were separated into four major fractions by gel chromatography. The proteins recovery was 96.72%. Of the four fractions, fraction B contained the highest TGF-beta1 and PDGF-AB levels, and the highest proteins concentrations. Cell proliferation curves of MSC demonstrated that fraction B and C induced a remarkable increase of MTT values compared to the untreated culture ($P < 0.05$), and the effects of fraction B and C showed no significant difference compared to the PRP group ($P > 0.05$). Fraction A and D showed no significant difference to the negative control group ($P > 0.05$). **CONCLUSIONS:** The growth factors in PRP supernatants could be preliminarily separated into four fractions by gel chromatography, and the freeze-drying fractions retained the biological activity of growth factors. The growth factors were mostly presented in fraction B and C, and they promoted cell proliferation effectively.

Publication Types:

- [Research Support, Non-U.S. Gov't](#)

PMID: 19187622 [PubMed - in process]

19: [Vet Dermatol](#). 2009 Apr;20(2):123-6. Epub 2009 Jan 21.

[Related Articles,
Links](#)



Curative effect of autologous platelet-rich plasma on a large cutaneous lesion in a dog.

[Kim JH](#), [Park C](#), [Park HM](#).

Department of Veterinary Internal Medicine, College of Veterinary Medicine, Konkuk University, Seoul 143-701, South Korea.

A dorsal tail mass (1 x 1.2 cm) was observed on a 10-year-old castrated male, Shih-tzu dog. A biopsy of the mass was performed and diagnosed histopathologically as a follicular cyst. A necrotic lesion (2.5 x 3 cm) developed at the biopsy site 1 week after sampling and failed to respond to 2 weeks of normal saline cleansing and systemic antibiotic administration. Autologous platelet-rich plasma was applied to the lesion which gradually improved over a 4-week period possibly by a contribution to the secretion of growth hormone, which can accelerate tissue regeneration. This case report suggests that autologous PRP may be beneficial in the management of large skin defects or in delayed wound healing.

Publication Types:

- [Research Support, Non-U.S. Gov't](#)

PMID: 19159413 [PubMed - in process]



Regenerative Surgery: Use of Fat Grafting Combined with Platelet-Rich Plasma for Chronic Lower-Extremity Ulcers.

[Cervelli V.](#), [Gentile P.](#), [Grimaldi M.](#)

Department of Plastic and Reconstructive Surgery, University of Tor Vergata, Rome, Italy.

BACKGROUND: The authors present their experience with reconstructive surgery of the lower extremity for chronic ulcers, evaluating the effects related to the use of a platelet-rich plasma combined with fat tissue. **METHODS:** A total of 20 patients, 25 to 50 years of age (median age, 40 years), have been managed with platelet gel in the Plastic and Reconstructive Surgery Department at the "Tor Vergata," University of Rome. The patients were affected by both lower-extremity chronic ulcers and vascular disease. **RESULTS:** The authors observed that 16 of 20 chronic lower-extremity ulcers reepithelialized during an average of 9.7 weeks, with platelet releasate suspended on a collagen base (platelet-derived wound-healing factor), compared with 2 of 10 similar wounds treated with medication based on hyaluronic acid and collagen. Collectively, these data provide evidence for the clinical use of platelet technology in the healing of both soft and hard tissue wounds. **CONCLUSIONS:** Currently, plastic surgery with autogenous fat grafts can be performed for stabilization of chronic lower-extremity ulcers. The objective of this study was, through the presentation of clinical cases, to suggest a therapeutic plan formed by two sequential treatments: acquisition of platelet gel from a small volume of blood (9-18 ml) followed by the Coleman technique for reconstructing the three-dimensional projection and superficial density of tissues. The results proved the efficacy of combining these two treatments, and the satisfaction of the patients confirmed the quality of the results.

PMID: 19156458 [PubMed - as supplied by publisher]



Platelet-rich plasma - A promising cell carrier for micro-invasive articular cartilage repair.

[Wu W.](#), [Zhang J.](#), [Dong Q.](#), [Liu Y.](#), [Mao T.](#), [Chen F.](#)

Department of Oral and Maxillofacial Surgery, Qin Du Hospital, School of Stomatology, Fourth Military Medical University, Changle West Road 145#, Xi'an 710032, PR China.

Due to the limited regenerative capacity of cartilage tissues, articular cartilage defect caused by various lesions remains a problem to be resolved. Tissue engineering provided a valuable alternative to current therapeutic approaches, which is expected to greatly reduce the need of joint replacement. Scaffold, acting as cell carrier, plays an important role in maintaining cells in defect sites, thus facilitates the chondrogenesis. However, an open operation is often needed to implant the cell/scaffold composite, to find a less invasive way to delivering the complex into the defect site would be desirable. Different from synthetic and other nature derived scaffold, platelet-rich plasma (PRP) is a fraction of plasma which contains multiple growth factors and could be clotted when mixed with thrombin. Therefore, we hypothesized that PRP could be used as an autologous cell carrier to inject and fix chondrocytes into the defect site of articular cartilage. With the assistance of arthroscope, the defect could be precisely located, and injectable PRP-Cell composite would make the operation micro-invasive and simple.

PMID: 19138823 [PubMed - in process]



The clinical use of platelet-rich plasma in the promotion of bone healing: a systematic review.

[Griffin XL](#), [Smith CM](#), [Costa ML](#).

Warwick Orthopaedics, Clinical Sciences Research Institute, University Hospital Coventry and Warwickshire, Department of Trauma and Orthopaedics, Clifford Bridge Road, Coventry CV2 2DX, UK. x.griffin@warwick.ac.uk

Platelet-rich plasma has been shown in several in vitro and animal studies to play a role in promoting new bone formation. A systematic literature review was conducted to identify the current relevant evidence base, searching across multiple sources including Medline, Embase and the Cochrane Library, and finding five clinically relevant articles. Only one was a randomised controlled trial, but this was underpowered for the outcome measure defined. Three studies exclusively concerned children, and included those with congenital limb deformities. Two other reports were case series. Early clinical results suggest that the use of platelet-rich plasma is safe and feasible, but that at present there is no clinical evidence of benefit in either acute or delayed fracture healing.

PMID: 19084836 [PubMed - in process]

23: [Zhongguo Xiu Fu Chong Jian Wai Ke Za Zhi](#). 2008 Nov;22(11):1301-5.

[Related Articles,](#)
[Links](#)

[Follow-up study on platelet-rich plasma in repairing chronic wound nonunion of lower limbs in 47 cases]

[Article in Chinese]

[Guo Y](#), [Qiu J](#), [Zhang C](#).

Department of Orthopedics, Sixth People's Affiliated Hospital of Shanghai Jiaotong University, Shanghai 200233, PR China.

OBJECTIVE: To study the effect of platelet-rich plasma (PRP) on repairing chronic wounds of lower limbs. **METHODS:** From May 2007 to November 2007, 47 patients suffering from chronic wounds of lower limbs were treated. There were 41 males and 6 females, aged from 15 to 68 years (43.2 years on average). The disease was caused by tibiofibula fracture in 20 cases, calcaneus fracture in 4 cases, metatarsal fracture in 1 case, multiple open fracture of lower limbs in 3 cases, tibia osteomyelitis in 10 cases, femur osteomyelitis in 1 case, soft tissue injury of ankle in 4 cases, infection after amputation in 2 cases, infection after foot orthomorphia in 1 case, and infection after calcaneus tendon neoplasty in 1 case. Their chronic wounds did not healed after 2 to 4 months of therapy. Among them, chronic wounds complicated with fracture nonunion in 23 cases and positive bacterial culture result in 38 cases. Debridement and autogenous PRP gel injection were applied every 2 months and for twice. **RESULTS:** The patients were followed up for 4 months after the first PRP injection. Two months after the first PRP injection, chronic wounds contracted significantly in 34 patients with purulence and necrosis tissue cleaned up, circulation of soft tissue improved and exposed bone or muscle tissue covered by neogenetic granulation. No patient was completely cured. Two months after the second PRP injection, the average coverage rate was 79.3% +/- 18.0%, the total cure rate was 29.8%. The volume of the chronic wounds decreased by (9.3 +/- 4.9) mL after PRP therapy (2.5 +/- 2.7) mL when compared with (11.8 +/- 5.6) mL of before therapy, showing significant difference ($P < 0.05$). X-ray photograph showed that among the 23 cases of fracture nonunion, fracture healed completely in 9 cases; bony callus formation increased obviously in 12 cases; no significant change was observed in 2 cases. No aggravated sign of osteomyelitis was notified. Positive results of bacterial culture reduced to 15 cases. **CONCLUSION:** PRP efficiently enhances

the recovery of soft tissue defect and speeds up the chronic wounds healing of lower limbs.

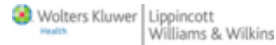Publication Types:

- [English Abstract](#)

PMID: 19068594 [PubMed - in process]

24: [Adv Skin Wound Care](#). 2008 Dec;21(12):568-75.

[Related Articles,](#)
[Links](#)



An evidence-based model comparing the cost-effectiveness of platelet-rich plasma gel to alternative therapies for patients with nonhealing diabetic foot ulcers.

[Dougherty E.J.](#)

B&D Consulting, Washington, DC, USA.

OBJECTIVE: A cost-effectiveness analysis compared the potential economic benefit of an autologous, platelet-rich plasma (PRP) gel to alternative therapies in treating nonhealing diabetic foot ulcers. **DESIGN:** An economic model used peer-reviewed data to simulate clinical and cost outcomes and quality-adjusted life-years (QALYs) associated with PRP gel and other treatment modalities. **PATIENTS:** The model varies rates of healing, recurrence, infection, amputation, death, and associated costs for a hypothetical group of 200,000 patients with full-thickness, nonhealing diabetic foot ulcers for 5 years or until death. **MAIN OUTCOME MEASURES:** The model simulates the clinical, cost, and QALY outcomes associated with PRP gel versus other modalities in treating nonhealing diabetic foot ulcers over a 5-year period. **MAIN RESULTS:** The average 5-year direct wound care cost per modality and QALYs were PRP gel, \$15,159 (2.87); saline gel, \$33,214 (2.70); standard of care, \$40,073 (2.65); noncontact kilohertz ultrasound therapy, \$32,659 (2.73); human fibroblast-derived dermal substitute, \$40,569 (2.65); allogenic bilayered culture skin substitute, \$24,374 (2.79); bilayered cellular matrix, \$37,340 (2.71); negative pressure wound therapy, \$20,964 (2.81); and recombinant human platelet-derived growth factor BB, \$47,252 (2.69). **CONCLUSION:** Use of PRP gel resulted in improved quality of life and lower cost of care over a 5-year period than other treatment modalities for nonhealing diabetic foot ulcers. Although actual treatment outcomes may differ from those modeled, PRP gel represents a potentially attractive treatment alternative for insurers and health care providers to address the cost burden and health effects of nonhealing diabetic foot ulcers.

Publication Types:

- [Comparative Study](#)
- [Research Support, Non-U.S. Gov't](#)

PMID: 19065083 [PubMed - indexed for MEDLINE]

25: [Clin Sports Med](#). 2009 Jan;28(1):113-25.

[Related Articles,](#)
[Links](#)



Treatment of tendon and muscle using platelet-rich plasma.

[Mishra A](#), [Woodall J.Jr](#), [Vieira A](#).

Department of Orthopedic Surgery, Menlo Medical Clinic, Stanford University Medical Center, 1300 Crane Street, Menlo Park, CA 94025, USA. am@totaltendon.com

Tendon and muscle injuries are common in elite and weekend athletes. Treatment of these injuries in both groups is rapidly evolving. Sports medicine patients are demanding better and less invasive solutions for all types of musculoskeletal disorders. In this context, platelet-rich plasma (PRP) has emerged as a potential solution. PRP is a fraction of whole blood containing concentrated growth factors and proteins. These cytokines direct tissue healing through autocrine and paracrine effects. The number of basic science, animal, and human investigations of PRP for tendon and muscle injuries worldwide has risen sharply in recent years. These studies are helping clinicians better understand the mechanisms of PRP and are guiding novel treatment protocols. In this paper, the value of PRP as a treatment for acute or chronic tendon and muscle disorders is explored.

Publication Types:

- [Review](#)

PMID: 19064169 [PubMed - indexed for MEDLINE]

□ 26: [Quintessence Int.](#) 2008 Jun;39(6):473-83.

[Related Articles,
Links](#)

Role of platelet-rich plasma in soft tissue root-coverage procedures: a review.

[Bashutski JD](#), [Wang HL](#).

Department of Periodontics and Oral Medicine, School of Dentistry, University of Michigan, Ann Arbor, MI 48109-1078, USA.

The aim of this article was to review the current evidence on the role of platelet-rich plasma (PRP) in enhancing root-coverage techniques and discuss the rationale for its use in these applications. Sound biologic rationale and a multitude of basic science research support the use of PRP to promote soft tissue healing, although evidence of its role in enhancing periodontal applications, especially root coverage, is limited. Current scientific research has yet to elucidate all of the mechanisms by which PRP can affect soft tissue healing and assess its capacity to stimulate regeneration. Furthermore, clinical evidence on the use of PRP in root-coverage procedures is extremely limited, with only 2 randomized controlled trials published as of May 2007. A pertinent review of medical and dental literature relating to PRP and its role in wound healing and enhancement of root-coverage procedures was performed. Preliminary reports in this area suggest that the potential benefits of PRP in root-coverage procedures may be improved esthetics, decreased patient morbidity, and accelerated wound healing. An appropriate assessment of the effects of PRP and its possible use in enhancing root-coverage procedures cannot be made at this time because of inadequate clinical evidence.

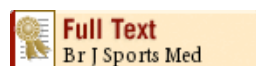Publication Types:

- [Research Support, Non-U.S. Gov't](#)
- [Review](#)

PMID: 19057743 [PubMed - indexed for MEDLINE]

□ 27: [Br J Sports Med.](#) 2009 Jan 21. [Epub ahead of print]

[Related Articles,
Links](#)



A systematic review of four injection therapies for lateral epicondylitis: prolotherapy, polidocanol, whole blood and platelet rich plasma.

University of Wisconsin, United States.

OBJECTIVE: To appraise existing evidence for prolotherapy, polidocanol, autologous whole blood and platelet-rich plasma injection therapies for lateral epicondylitis (LE). **DESIGN:** Systematic Review. **DATA SOURCES:** Medline, Embase, CINAHL, Cochrane Central Register of Controlled Trials, Allied and Complementary Medicine. **Search strategy:** names and descriptors of the therapies and LE. **Study Selection:** All human studies assessing the four therapies for LE. **MAIN RESULTS:** Results of five prospective case series and four controlled trials (3 prolotherapy, 2 polidocanol, 3 autologous whole blood and 1 platelet-rich plasma) suggest each of the four therapies is effective for LE. In follow-up periods ranging from 9 to 108 weeks, studies reported sustained, statistically significant ($p < 0.05$) improvement on visual analog scale primary outcome pain score measures and disease specific questionnaires; relative effect sizes ranged from 51% to 94%; Cohen's d ranged from 0.68 to 6.68. Secondary outcomes also improved, including biomechanical elbow function assessment (polidocanol and prolotherapy), presence of abnormalities and increased vascularity on ultrasound (autologous whole blood and polidocanol). Subjects reported satisfaction with therapies on single-item assessments. All studies were limited by small sample size. **CONCLUSIONS:** There is strong pilot-level evidence supporting the use of prolotherapy, polidocanol, autologous whole blood and platelet-rich plasma injections in the treatment of LE. Rigorous studies of sufficient sample size, assessing these injection therapies using validated clinical, radiological and biomechanical measures, and tissue injury/healing-responsive biomarkers, are needed to determine long-term effectiveness and safety, and whether these techniques can play a definitive role in the management of LE and other tendinopathies.

PMID: 19028733 [PubMed - as supplied by publisher]

-
- **28:** [Med J Malaysia](#). 2008 Jul;63 Suppl A:41.

[Related Articles,](#)
[Links](#)

Cell therapy for facial anti-aging.

[Ebisawa K](#), [Kato R](#), [Okada M](#), [Kamei Y](#), [Mazlyzam AL](#), [Narita Y](#), [Kagami H](#), [Ueda M](#).

Department of Oral and Maxillofacial Surgery, Graduate School of Medicine, Nagoya University, Nagoya, Japan.

Two types of cell therapy for facial anti-aging in my clinical experience are introduced in this presentation. One therapy is cultured gingival fibroblasts injection. This procedure lasts for at least one year, making it a good option for patients. The other is platelet rich plasma injection. The results of the preliminary data are promising, but not yet well understood. More clinical data and long-term follow-up is needed.

PMID: 19024974 [PubMed - indexed for MEDLINE]

-
- **29:** [J Orthop Res](#). 2008 Nov 7. [Epub ahead of print]

[Related Articles,](#)
[Links](#)



Platelet-rich plasma alone is not sufficient to enhance Suture Repair of the ACL in skeletally immature animals: An in vivo study.

[Murray MM](#), [Palmer M](#), [Abreu E](#), [Spindler KP](#), [Zurakowski D](#), [Fleming BC](#).

Department of Orthopaedic Surgery, Children's Hospital Boston, 300 Longwood Avenue, Boston, Massachusetts 02115.

In this study, we hypothesize that supplementation of suture repair of the anterior cruciate ligament (ACL) with platelet-rich plasma (PRP) will improve the biomechanics of the repair. Six 30-kg pigs underwent bilateral suture repair of the ACL. One side was treated with suture repair alone, while the contralateral side was treated with suture repair augmented with PRP. After 14 weeks in vivo, anterior-posterior (AP) knee laxity and the tensile properties of the repaired ligament were measured. The addition of PRP to the suture repairs did not improve AP knee laxity at 30 degrees ($p = 0.73$) or 60 degrees ($p = 0.65$). It also did not improve the maximum tensile load ($p = 0.64$) or linear stiffness ($p = 0.42$) of the ACL repairs after 14 weeks in vivo. The model had 80% power to detect a 30% improvement of biomechanical properties with PRP; thus, we are confident that a clinically meaningful effect as a result of adding PRP is unlikely. Use of PRP alone to supplement suture repair of the ACL is ineffective in this animal model. Published by Wiley Periodicals, Inc. J Orthop Res.

PMID: 18991345 [PubMed - as supplied by publisher]

□ 30: [J Laryngol Otol](#). 2008 Oct 28;1-6. [Epub ahead of print]

[Related Articles,](#)
[Links](#)

Platelet-rich plasma improves healing of tympanic membrane perforations: experimental study.

[Erkilet E](#), [Koyuncu M](#), [Atmaca S](#), [Yarim M](#).

Department of Otolaryngology and Head and Neck Surgery, School of Medicine, Ondokuz Mayıs University, Samsun, Turkey.

Objective:The aim of this study was to investigate the effect of local application of platelet-rich plasma to perforated rat tympanic membranes, in terms of healing time and histopathological outcome.**Methods:**Eighty-eight tympanic membranes of 44 rats were given a standard 3 mm perforation, and platelet-rich plasma was applied to the right tympanic membrane perforations. The left tympanic membranes were left to heal spontaneously, as controls. The 44 rats were divided into two groups. In group one, comprising 20 rats, daily otomicroscopic examination of the tympanic membrane perforations was performed. The 24 rats in group two were subdivided into four subgroups of six rats each; these subgroups were sacrificed sequentially on days three, seven, 14 and 28 for histopathological examination, regardless of tympanic membrane healing stage.**Results:**In group one, the mean tympanic membrane healing times for tympanic membrane perforations receiving platelet-rich plasma and controls were respectively 10.2 +/- 2.1 and 13.0 +/- 2.9 days (mean +/- standard deviation). This difference was statistically significant ($p < 0.001$). In group two, histopathological evaluation of tympanic membrane perforation healing at days three, seven, 14 and 28 did not reveal any statistically significant difference, individually or within the four groups as a whole.**Conclusion:**These findings suggest that earlier healing of tympanic membrane perforations occurred in the platelet-rich plasma group compared with the control group. These findings suggest that platelet-rich plasma is effective in accelerating tympanic membrane perforation healing, and that it may be effective in human subjects, particularly as it is an autologous material.

PMID: 18954495 [PubMed - as supplied by publisher]

□ 31: [Transfusion](#). 2009 Jan;49(1):44-56. Epub 2008 Oct 14.

[Related Articles,](#)
[Links](#)



Efficacy and safety of the use of autologous plasma rich in platelets for tissue regeneration: a systematic review.

[Martínez-Zapata MJ](#), [Martí-Carvajal A](#), [Solà I](#), [Bolibar I](#), [Angel Expósito J](#), [Rodríguez L](#), [García J](#).

BACKGROUND: Autologous plasma rich in platelets (PRP) is a derived blood product whose application in clinical practice is growing. A systematic review was conducted to evaluate its efficacy and safety. **STUDY DESIGN AND METHODS:** A search was performed in electronic databases. Randomized controlled clinical trials (RCTs) in adult patients were included and assessed for methodologic quality. The main outcomes were "tissue regeneration" and "safety." Relative risks (RRs) and standardized mean differences (SMDs) were calculated to show pooled estimates for these outcomes. When the results heterogeneity was more than 50 percent, a sensitivity analysis was performed. **RESULTS:** Twenty RCTs were included (11 of oral and maxillofacial surgery, 7 of chronic skin ulcers, and 2 of surgery wounds). Four RCTs evaluated the depth reduction in gingival recession in chronic periodontitis; the SMD was 0.54 (95% confidence interval [CI], 0.16 to 0.92) mm, favorable to PRP. Three RCTs evaluated the clinical attachment level in chronic periodontitis; the SMD was 0.33 (95% CI, -0.71 to 1.37) mm. Six RCTs assessed the complete skin epithelialization in wound ulcers; the RR was 1.40 (95% CI, 0.85 to 2.31). Only 6 RCTs reported adverse effects without differences between groups. **CONCLUSIONS:** PRP improves the gingival recession but not the clinical attachment level in chronic periodontitis. In the complete healing process of chronic skin ulcers, the results are inconclusive. There are little data about PRP safety. There are several methodologic limitations and, consequently, future research should focus on strong and well-designed RCTs that assess the efficacy and safety of PRP.

Publication Types:

- [Research Support, Non-U.S. Gov't](#)
- [Review](#)

PMID: 18954394 [PubMed - indexed for MEDLINE]

32: [J Orthop Trauma](#). 2008 Oct;22(9):595-604.

[Related Articles,
Links](#)



Platelet-rich concentrate supports human mesenchymal stem cell proliferation, bone morphogenetic protein-2 messenger RNA expression, alkaline phosphatase activity, and bone formation in vitro: a mode of action to enhance bone repair.

[Parsons P](#), [Butcher A](#), [Hesselden K](#), [Ellis K](#), [Maughan J](#), [Milner R](#), [Scott M](#), [Alley C](#), [Watson JT](#), [Horner A](#).

Smith & Nephew Research Centre, Heslington, York, UK.

OBJECTIVE: Platelet-rich concentrate (PRC) is an autologous growth factor preparation that is in routine use for orthopaedic and maxillofacial surgery. However, there are little data available describing the cellular and molecular mechanisms by which PRC enhances the healing response in an osseous environment. The aim of this study was to identify cellular and molecular events that are modulated in human mesenchymal stem cells (hMSCs) in response to exposure to human PRC generated by a novel filtration-based device (CAPTION, Smith & Nephew Inc). **METHODS:** PRC and serum were prepared from blood donated by 11 volunteers. Growth factor content and release from PRC were determined by enzyme-linked immunosorbent assay. Cell proliferation was quantified by DNA content and osteoblastic differentiation by alkaline phosphatase expression and mineralized nodule formation. Real-time reverse transcription-polymerase chain reaction analysis was used to determine the early molecular pathways regulated in hMSCs by PRC. **RESULTS:** The results obtained confirm previous in vitro and in vivo observations demonstrating that PRC enhances hMSC proliferation. Furthermore, our data suggest that when added as a clot, PRC

induces an earlier onset of proliferation compared with serum without leading to cell overgrowth and the inhibition of cell differentiation. At the molecular level, PRC treatment stimulated a transient enhancement of bone morphogenetic protein-2 messenger RNA that peaked after 12 hours and induced an earlier and a sustained increase in the key osteogenic transcription factor RUNX2. By 3 days of treatment, PRC enhanced alkaline phosphatase activity more than 2-fold compared with donor-matched serum, and at 23 days, the increase in osteoblastic commitment translated to enhanced calcified matrix deposition.

CONCLUSIONS: Taken together, the data presented here suggest that treatment of hMSC with clotted PRC, in an osteoinductive environment, enhances osteoblastic commitment and bone formation. Furthermore, these data indicate that the enhanced osteogenesis seen in the presence of PRC cannot be explained solely by enhanced cell proliferation, suggesting that PRC modulates a number of cell and molecular pathways to promote bone formation.

PMID: 18827588 [PubMed - indexed for MEDLINE]

33: [Acta Chir Orthop Traumatol Cech.](#) 2008 Aug;75(4):247-52.

[Related Articles, Links](#)

[The role of growth factors in the human organism and their use in medicine, especially in orthopedics and traumatology]

[Article in Czech]

[Frei R](#), [Biosca FE](#), [Handl M](#), [Trc T](#).

Klinika detské a dospělé ortopedie a traumatologie 2. LF UK a FN Motol, Praha.

The authors analyze one of the new therapeutic approaches - the use of autologous growth factors. Because the chemical structure of these proteins and their involvement in many functions of the organism affect the whole range of tissues, with a possibility to use them in human medicine. Growth factors, such as platelet-derived growth factor, transforming growth factor and others, exert effects on fibroplastic events during ontogenesis as well as on regeneration of tissues injured due to an accident or surgery. The preparation of therapeutic doses of growth factors consists of autologous blood collection, plasma separation and application of plasma rich in growth factors. The fibroplastic event involves chemotaxis and proliferation of cells, proteosynthesis, reparation and remodeling of tissues. The paper describes the method and is an introduction to studies on the utilization of growth factors in orthopaedics and traumatology.

Publication Types:

- [English Abstract](#)
- [Review](#)

PMID: 18760079 [PubMed - indexed for MEDLINE]

34: [Ann Plast Surg.](#) 2008 Sep;61(3):337-44.

[Related Articles, Links](#)



Role of platelet-rich plasma in acceleration of bone fracture healing.

[Simman R](#), [Hoffmann A](#), [Bohinc RJ](#), [Peterson WC](#), [Russ AJ](#).

Department of Surgery, Division of Plastic Surgery, Boonshoft School of Medicine, Wright State University, Dayton, OH, USA. Richard.simman@wright.edu

Platelet-rich plasma (PRP) is a common therapy for acceleration of maxillofacial and spinal fusion bone-graft healing. This study analyzes the therapeutic role of PRP during long-bone

fracture healing evaluated Lewis rats. Following creation of unilateral open femur fractures, either 500 microL thrombin-activated PRP (PRP treated group) or 500 microL saline (control group) were applied once to the fracture site. Fracture healing was analyzed after 1 and 4 weeks. Following 4 weeks of fracture healing, radiographic analysis demonstrated higher callus to cortex width ratio ($P < 0.05$) in the PRP group (PRP: 1.65 ± 0.06 ; control: 1.48 ± 0.05). Three-point load bearing showed increased bone strength following PRP treatment (PRP: 60.85 ± 6.06 Newton, control: 47.66 ± 5.49 Newton). Fracture histology showed enhanced bone formation in the PRP group. Immunohistochemistry and Western-blotting demonstrated healing-associated changes in transforming growth factor (TGF)-beta1 and bone morphogenetic protein (BMP)-2. Our results suggest that PRP accelerates bone fracture healing of rat femurs via modulation of TGF-beta1 and BMP-2 growth factor expression.

PMID: 18724139 [PubMed - indexed for MEDLINE]

35: [Injury](#). 2008 Aug 12. [Epub ahead of print]

[Related Articles,](#)
[Links](#)



The use of autologous PRP gel as an aid in the management of acute trauma wounds.

[Kazakos K](#), [Lyras DN](#), [Verettas D](#), [Tilkeridis K](#), [Tryfonidis M](#).

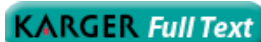Department of Orthopaedics, Democritus University Hospital of Thrace, University of Thrace, Dragana, Alexandroupolis, B.O. 84100, Greece.

Autologous platelet-rich plasma (PRP) gel is increasingly used in the treatment of a variety of soft and bony tissue defects, such as accelerating bone formation and in the management of chronic non-healing wounds. We performed this study to assess the benefits of using autologous PRP gel in the treatment of acute limb soft tissue wounds. 59 patients with acute wounds (open fractures, closed fractures with skin necrosis and friction burns) were randomised into two groups. Group A (32 patients) were treated with conventional dressings and Group B (27 patients) were managed with local application of PRP gel. Gustillo grade IIIb or IIIc open fractures were not included in this study, as these injuries required coverage with flap. The clinical endpoints were the healing rate and/or the time required to bring about adequate tissue regeneration in order to undergo reconstructive plastic surgery. The rate of wound healing rate was significantly faster in Group B at week 1, 2 and 3 ($p=0.003$, $p<0.001$ and $p<0.001$, respectively). The mean time to plastic reconstruction in Group B was 21.26 days, S.D.=1.35 vs 40.6 days in Group A, S.D.=5.27 ($p<0.001$). This study has shown that PRP gel treatment can be a valuable and effective aid in the management of acute trauma wounds.

PMID: 18703188 [PubMed - as supplied by publisher]

36: [Cells Tissues Organs](#). 2009;189(5):317-26. Epub 2008 Aug 11.

[Related Articles,](#)
[Links](#)



Influence of platelet-rich plasma on chondrogenic differentiation and proliferation of chondrocytes and mesenchymal stem cells.

[Drengk A](#), [Zapf A](#), [Stürmer EK](#), [Stürmer KM](#), [Frosch KH](#).

Department of Trauma Surgery, Plastic and Reconstructive Surgery, Georg August University Göttingen, Göttingen, Germany.

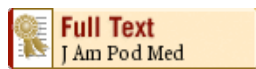BACKGROUND/AIMS: Autologous chondrocyte (CC) transplantation has the disadvantages of requiring two surgical interventions and in vitro expansion of cells, implying the risk of cellular dedifferentiation. Our clinical aim is to develop a one-step

procedure for autologous CC transplantation, i.e. harvesting, isolation and reimplantation of CC performed in one single surgical procedure. Platelet-rich plasma (PRP) is a source of autologous growth factors reported to have mitogenic effects. The objective of this study was to test the influence of PRP as an autologous scaffold on freshly isolated CC and mesenchymal stem cells (MSC). METHODS: CC and MSC were subjected to two- or three-dimensional (3D) growth systems, either with or without PRP. Chondrogenic differentiation was determined via quantification of collagen type II mRNA and immunohistochemical staining. RESULTS: We observed a proliferative effect for MSCs exposed to PRP in monolayer culture and an increase in the expression of chondrogenic markers when cells are exposed to a 3D environment. CCs exposed to PRP show a decrease in the chondrogenic phenotype with increasing proliferative activity. CONCLUSION: PRP has a proliferative effect on CCs and MSCs. In a one-step procedure for autologous CC transplantation, this might be an advantage over other scaffold materials, but confirmation in in vivo studies is required. 2008 S. Karger AG, Basel.

PMID: 18689989 [PubMed - in process]

□ 37: [J Am Podiatr Med Assoc.](#) 2008 Jul-Aug;98(4):296-301.

[Related Articles,](#)
[Links](#)



Platelet gel for the surgical treatment of onychocryptosis.

[Córdoba-Fernandez A](#), [Rayo-Rosado R](#), [Juarez-Jiménez JM](#).

Department of Podiatry, Seville University, Seville, Spain. acordoba@us.es

BACKGROUND: The growth factors derived from platelets contained in platelet-rich plasma comprise a series of molecules that favor the production of collagen with the proliferation of fibroblasts and new blood vessels. These substances exert their effect on the cells, acting in all the stages of cicatrization, especially in hemostasis and early fibroplasia. METHODS: Thirty-five patients (70 feet) were selected, operated on both sides for ingrown hallux nails, and subjected to two different experimental conditions in a crossover clinical trial with positive control of treatment. Two main variables were analyzed: on one side, the bleeding, according to three preestablished categories, and on the other, the mean time of cicatrization in days. RESULTS: Significant differences ($P < .001$) were found between the two groups for bleeding. We observed that cicatrization time did not differ significantly between the two treatments. CONCLUSION: The use of platelet gel for the treatment of onychocryptosis by single nonincisional matricectomy can guarantee good hemostasis, with a significant reduction in bleeding, but does not produce a clinically significant reduction in cicatrization time.

Publication Types:

- [Randomized Controlled Trial](#)

PMID: 18685050 [PubMed - indexed for MEDLINE]

□ 38: [Biomaterials.](#) 2008 Oct;29(29):3983-92. Epub 2008 Jul 9.

[Related Articles,](#)
[Links](#)



The effect of platelet-rich plasma on healing in critical-size long-bone defects.

[Kasten P](#), [Vogel J](#), [Geiger E](#), [Niemeyer P](#), [Luginbühl R](#), [Szalay K](#).

Orthopaedic Surgery Hospital, University of Heidelberg, Schlierbacher Landstrasse 200a, 69118 Heidelberg, Germany. Philip.Kasten@ok.uni-heidelberg.de

The role of platelet-rich plasma (PRP) as a promoter of bone healing remains controversial. The hypothesis investigated was that PRP improves bone healing of a critical-size diaphyseal radius defect in a rabbit model. The bone defect was filled with a high-surface ceramic scaffold, calcium-deficient hydroxyapatite (CDHA), with the addition of allogenic PRP, mesenchymal stem cells (MSC) or both. PRP yielded better bone formation than the empty CDHA scaffold as determined by both histology and micro-computer tomography ($p < 0.05$) after 16 weeks, whereas no difference was observed on biomechanical testing. Similar behavior was found in samples with MSC; however, the combination of MSC and PRP did not further improve bone healing. Furthermore, the resorption of CDHA was improved by the addition of PRP, MSC and MSC/PRP, but there were no differences between the groups. The areas of bone formation were greater in areas adjacent to the bone resection areas and towards the intact ulna. In conclusion, PRP improves bone healing in a diaphyseal rabbit model on CDHA and the combination of CDHA. This study supports the allogenic use of PRP for bone healing as an off-the-shelf therapy.

Publication Types:

- [Evaluation Studies](#)
- [Research Support, Non-U.S. Gov't](#)

PMID: 18614227 [PubMed - indexed for MEDLINE]

39: [Disabil Rehabil.](#) 2008;30(20-22):1584-9.

[Related Articles,](#)
[Links](#)



Autologous platelet rich plasma for arthroscopic rotator cuff repair. A pilot study.

[Randelli PS](#), [Arrigoni P](#), [Cabitza P](#), [Volpi P](#), [Maffulli N](#).

Dipartimento di Scienze Medico-Chirurgiche, Policlinico San Donato, Università degli Studi di Milano, Milano, Italy.

BACKGROUND AND PURPOSE: Arthroscopic repair of rotator cuff tears can produce excellent results. The application of platelet rich plasma during arthroscopic rotator cuff repair is safe, and produces results which do not deteriorate over time. **METHODS:** A total of 14 patients undergoing arthroscopic repair of a rotator cuff tear received an intra-operative application of autologous platelet rich plasma in combination with an autologous thrombin component after tear repair. Following the procedure, patients were given a standardized rehabilitation protocol, and followed for 24 months. Outcome measures included a pain score (VAS) as well as functional scoring (UCLA and Constant scores). **RESULTS:** Of the original 14 patients, 13 were seen at a final follow-up appointment 24 months after the index operation. Patients demonstrated a significant decrease in VAS scores and significant increases in the UCLA and Constant scores at 6, 12 and 24-month follow-ups compared to a pre-operative score. **CONCLUSION:** No adverse events related to this application were noted during the procedure. The application of platelet rich plasma during arthroscopic rotator cuff repair is safe and effective, and produces results which seem to be stable with time. A prospective randomized investigation will be necessary to ascertain the efficacy of platelet rich plasma application to improve or expedite the surgical outcome following arthroscopic rotator cuff repair.

PMID: 18608363 [PubMed - indexed for MEDLINE]

40: [Coron Artery Dis.](#) 2008 Aug;19(5):363-70.

[Related Articles,](#)
[Links](#)



Effects of intramyocardial injection of platelet-rich plasma on the healing

process after myocardial infarction.

[Li XH](#), [Zhou X](#), [Zeng S](#), [Ye F](#), [Yun JL](#), [Huang TG](#), [Li H](#), [Li YM](#).

Institute of Cardiovascular Disease, Pingjin Hospital, Medical College of Armed Police Forces, China.

OBJECTIVE: Platelet activation and subsequent release of granules containing a variety of growth factors, at the site of injury, is crucial for the wound healing process. We postulated that a platelet-mediated paracrine effect may accelerate the healing process after myocardial infarction. **METHODS:** Allogenic platelet-rich and platelet-poor plasma (PRP and PPP) were collected from 15 healthy male Wistar rats. After thrombin activation, the level of vascular endothelial growth factor (VEGF) in PRP and PPP was measured by enzyme-linked immunosorbent assay. A rat model of myocardial infarction was induced by permanent ligation of the left anterior descending artery, and thrombin-activated PRP and PPP, respectively, were injected into the ischemic region. Seven days and 28 days after operation, surviving rats were killed. Ex-vivo left ventricular pressure-volume relationship was performed to evaluate passive diastolic function. Collagen analysis was performed by picrosirius red staining plus polarized microscopy. Angiogenesis and arteriogenesis were evaluated by immunofluorescent staining. **RESULTS:** After thrombin activation, VEGF level in PRP was significantly higher than that in PPP (187.5+/-45.5 vs. 30.1+/-7.8 pg/ml, P<0.01). Injection of thrombin-activated PRP into the infarcted area resulted in improvement of ventricular remodeling and accelerated healing, as demonstrated by limitation of ventricular expansion, attenuation of myocardial hypertrophy in the noninfarct region, facilitation of angiogenesis and arteriogenesis in the infarct. **CONCLUSION:** Injection of thrombin-activated PRP could modulate favorably the postinfarction remodeling process. Platelet-released VEGF may participate in this protective effect.

Publication Types:

- [Research Support, Non-U.S. Gov't](#)

PMID: 18607174 [PubMed - indexed for MEDLINE]

41: [Tissue Eng Part B Rev](#). 2008 Sep;14(3):249-58.

[Related Articles,
Links](#)

Mary Ann Liebert,

The biology of platelet-rich plasma and its application in oral surgery: literature review.

[Nikolidakis D](#), [Jansen JA](#).

Department of Periodontology and Biomaterials, Radboud University Nijmegen Medical Center, Nijmegen, The Netherlands.

Platelet-rich plasma (PRP) is a new approach in tissue regeneration and a developing area for clinicians and researchers. It is used in various surgical fields, including oral and maxillofacial surgery. PRP is prepared from the patient's own blood and contains growth factors that influence wound healing. Of these growth factors, platelet-derived growth factor, transforming growth factor, insulin-like growth factor, and epidermal growth factor play a pivotal role in tissue repair mechanisms. Although the growth factors and mechanisms involved are still poorly understood, the easy application of PRP in the clinic and its possible beneficial outcome, including reduction of bleeding, rapid soft tissue healing, and bone regeneration, hold promise for new treatment approaches. However, animal studies and human trials demonstrate conflicting results regarding the application of PRP. Therefore the aim of this literature review is to evaluate the scientific evidence regarding the use of PRP in dentistry, to describe the different bioactive substances included in PRP and their participation in the healing process, to elucidate the different techniques and available technology for PRP preparation, to review animal and human studies, to

clarify risks, and to provide guidance for future research.

PMID: 18601587 [PubMed - in process]

42: [J Orthop Trauma](#). 2008 Jul;22(6):432-8.

[Related Articles,](#)
[Links](#)



Platelet rich concentrate: basic science and current clinical applications.

[Mehta S, Watson JT.](#)

Department of Orthopaedic Surgery, University of Pennsylvania Health System,
Philadelphia, Pennsylvania 19104, USA. samir.mehta@uphs.upenn.edu

Improvements in resuscitation, dissemination of ATLS protocols, and growth of regional and local trauma centers has increased the survivability after severe traumatic injuries. Furthermore, advances in medical management have increased life expectancy and also patients with orthopaedic injuries. While mechanical stabilization has been a hallmark of orthopaedic fracture care, orthobiologics are playing an increasing role in the management of these patients with complex injuries. Platelet-rich concentrate is an autologous concentration of platelets and growth factors, including transforming growth factor-beta (TGF-beta), vascular endothelial growth factor (VEGF), and platelet-derived growth factor (PDGF). The enhancement of bone and soft tissue healing by the placement of supraphysiologic concentration of autologous platelets at the site of tissue injury or surgery is supported by basic science and clinical studies. Due to the increased concentration and release of these factors, platelet-rich plasma can potentially enhance the recruitment and proliferation of tenocytes, stem cells, and endothelial cells. A better understanding of platelet function and appropriate clinical use is essential in achieving the desired outcomes of platelet-rich concentrate in orthopaedic clinical applications.

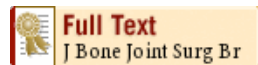Publication Types:

- [Research Support, Non-U.S. Gov't](#)
- [Review](#)

PMID: 18594311 [PubMed - indexed for MEDLINE]

43: [J Bone Joint Surg Br](#). 2008 Jul;90(7):966-72.

[Related Articles,](#)
[Links](#)



The effect of the platelet concentration in platelet-rich plasma gel on the regeneration of bone.

[Kawasumi M, Kitoh H, Siwicka KA, Ishiguro N.](#)

Department of Orthopaedic Surgery, Nagoya University School of Medicine, Showa-ku
Nagoya, Aichi 466-8550, Japan. kawasumi@med.nagoya-u.ac.jp

The aim of our study was to investigate the effect of platelet-rich plasma on the proliferation and differentiation of rat bone-marrow cells and to determine an optimal platelet concentration in plasma for osseous tissue engineering. Rat bone-marrow cells embedded in different concentrations of platelet-rich plasma gel were cultured for six days. Their potential for proliferation and osteogenic differentiation was analysed. Using a rat limb-lengthening model, the cultured rat bone-marrow cells with platelet-rich plasma of variable concentrations were transplanted into the distraction gap and the quality of the regenerate bone was evaluated radiologically. Cellular proliferation was enhanced in all the platelet-rich plasma groups in a dose-dependent manner. Although no significant differences in the

production and mRNA expression of alkaline phosphatase were detected among these groups, mature bone regenerates were more prevalent in the group with the highest concentration of platelets. Our results indicate that a high platelet concentration in the platelet-rich plasma in combination with osteoblastic cells could accelerate the formation of new bone during limb-lengthening procedures.

PMID: 18591611 [PubMed - indexed for MEDLINE]

44: [Eur J Cardiothorac Surg.](#) 2008 Aug;34(2):360-4. Epub 2008 Jun 26.

[Related Articles,](#)
[Links](#)



Topical application of autologous blood products during surgical closure following a coronary artery bypass graft.

[Khalafi RS](#), [Bradford DW](#), [Wilson MG](#).

North Texas Affiliated Medical Group, Fort Worth, TX 76104, USA.

OBJECTIVE: Surgical site wound complications are associated with increased cost, morbidity, and mortality following cardiothoracic surgery. Recent publications have advocated the application of autologous blood components as an adjunctive tool to surgical closure during various surgical procedures. The current study was intended to assess the safety and efficacy of the application of autologous platelet rich and platelet poor plasma to the sternal closure and saphenous vein harvest site during closure following a coronary artery bypass graft. **PATIENTS AND METHODS:** A retrospective analysis was performed on 1446 consecutive coronary artery bypass grafting procedures from two surgeons. A patient group receiving topical application of platelet rich and platelet poor plasma during closure of their chest and leg surgical incisions was compared to a patient population receiving standard treatment of care. Forty covariates were collected for each patient included in the study. Propensity scoring was used to adjust for baseline imbalance. Asymptotic logistic regression and exact statistical methods were used to determine the effect of the autologous blood application on infection and drainage of the sternal and leg wounds. **RESULTS:** One thousand, one hundred and twenty-eight patients had sufficient data to be included in the final analysis, with 571 of these patients receiving the treatment compared to 557 control patients. No treatment-related adverse events were noted and the application process did not significantly affect the operative time. **CONCLUSION:** This retrospective analysis of a consecutive series of patients receiving a coronary artery bypass grafting procedure concluded that application of platelet rich and platelet poor plasma significantly reduced occurrences of chest wound infection, chest drainage, and leg wound drainage. This novel therapy merits further investigation.

Publication Types:

- [Evaluation Studies](#)
- [Multicenter Study](#)
- [Research Support, Non-U.S. Gov't](#)

PMID: 18585051 [PubMed - indexed for MEDLINE]

45: [Int J Oral Maxillofac Surg.](#) 2008 Aug;37(8):748-55. Epub 2008 Jun 25.

[Related Articles,](#)
[Links](#)



Platelet rich plasma may enhance peripheral nerve regeneration after cyanoacrylate reanastomosis: a controlled blind study on rats.

[Elgazzar RF](#), [Mutabagani MA](#), [Abdelaal SE](#), [Sadakah AA](#).

The aim of this study was to explore the ability of platelet rich plasma (PRP) to promote peripheral nerve regeneration after cyanoacrylate reanastomosis in rats. A total of 18 rats were used in this study. Bilateral sciatic neurotomies were performed in 15 rats, and then immediately reanastomosed with cyanoacrylate glue. On one side (G1), the anastomosed nerves were treated with prepared autologous PRP gel; on the contralateral side (G2) the nerves received no additional treatment. Sham surgery was undertaken on the remaining 3 rats (6 cases) where bilateral sciatic nerves were surgically approached but not cut (passive control group, (G3). Biopsies were harvested 12 weeks postoperatively and examined under the light microscope using osmic acid stain. The number of nerve fibers in the distal and proximal nerve segments of G1 and G2 as well as in G3 were counted and the results analyzed and compared. Animals in G1 and G2 showed some weakness and ulceration in their right and left feet for a few weeks postoperatively, which gradually improved during the follow-up period. The histomorphometric assessment showed a higher axon count in the distal segment of G1 (291.7 axons) compared with that of G2 (280.5 axons) ($P=0.001$). Similar results were noticed when the proximal segments of both groups were compared ($P=0.040$). These results were reflected in the values of the neurotization indices of G1 (91.9%) and G2 (89.5%) ($P=0.008$). The number of nerve fibers in G1 and G2 remained lower than in G3 ($P=0.0001$). The authors conclude that PRP may enhance the number of regenerating nerve fibers after cyanoacrylate neuroanastomosis.

PMID: 18583097 [PubMed - indexed for MEDLINE]

46: [Transfusion](#). 2008 Jul;48(7):1469-77. Epub 2008 May 13.

[Related Articles](#),
[Links](#)



Platelet products prepared by different methods of sedimentation undergo platelet activation differently during storage.

[Skripchenko A](#), [Kurtz J](#), [Moroff G](#), [Wagner SJ](#).

The American Red Cross Biomedical Services, Holland Laboratory, Blood Components Development, Rockville, Maryland 20855, USA. skripcha@usa.redcross.org

BACKGROUND: The activation marker CD40 ligand (CD40L) has recently been demonstrated to be released from the cytoplasm of platelets (PLTs) during storage. CD40L may be associated with some adverse transfusion reactions including febrile responses and transfusion-related acute lung injury. CD62P has been traditionally measured to assess PLT activation. This study compares the surface levels of CD40L and CD62P and accumulation of the soluble forms of these activation markers in the plasma of stored PLTs, prepared by PLT-rich plasma (PRP) or buffy coat (BC) methods and with two apheresis instruments. **STUDY DESIGN AND METHODS:** Individual PLT concentrates (PCs) were prepared in 100 percent plasma from a pool of two ABO-identical whole-blood units. Apheresis PLTs (APs) were prepared in 100 percent plasma using one of two commercially available cell separators (Amicus, Baxter Healthcare; and Trima, Gambro BCT). Surface expression of CD40L and CD62P was measured by flow cytometry, and secretion of soluble CD40L (sCD40L) and soluble CD62 (sCD62) was measured by enzyme-linked immunosorbent assay during 7 days of PLT storage. **RESULTS:** Secretion of sCD40L was greater in Amicus APs than in Trima APs during the first 3 days of storage. It was also greater in the PRP-PC preparations than in BC-PC preparations through the first day of storage. Surface expression of CD40L was low in all PLT preparations. Secretion of sCD62P was greater in Amicus APs than in Trima APs during the entire storage period and greater in PRP-PC than in BC during the first 5 days of storage. The percentage of CD62P-positive PLTs was greater in Amicus units than Trima units and greater in PRP-PC than BC-PC preparations during the first 5 and 3 days of storage, respectively. **CONCLUSION:** The kinetics of the secretion of CD40L are influenced by the method used to prepare PLTs for storage. The patterns for CD40L membrane association and secretion are different than those observed for CD62P during storage.

47: [J Reconstr Microsurg](#). 2008 Apr;24(3):159-67. Epub 2008 Apr 30.

[Related Articles,](#)
[Links](#)



Effect of platelet-rich plasma on peripheral nerve regeneration.

[Sariguney Y](#), [Yavuzer R](#), [Elmas C](#), [Yenicesu I](#), [Bolay H](#), [Atabay K](#).

Department of Plastic, Reconstructive and Aesthetic Surgery, Gazi University Faculty of Medicine, Ankara, Turkey.

Activated platelets release various growth factors, some of which are recognized to improve nerve regeneration. This study evaluated the effect of platelet-rich plasma (PRP) in end-to-end neurorrhaphy. A total of 45 Wistar rats were used, with the initial five used for PRP preparation. The right hind limbs were used as experimental, with the left as control. The animals were treated in five groups. Group A (n = 4): The right sciatic nerve was dissected only from the sciatic notch to the bifurcation. In all other groups, the nerve was sharply transected and repaired with: group B (n = 8): two sutures; group C (n = 8): six sutures; group D (n = 10): two sutures and PRP; and group E (n = 10): six sutures and PRP. Groups D and E were compared with groups B and C, respectively. Group E had a shorter latency time in electromyography (P < 0.01) and a thicker myelin layer in the histological evaluation (P < 0.003) in comparison with group C. These positive effects of PRP were not detected in the nerves were repaired with two sutures. In this animal model, the application of PRP to the repair site helped to improve remyelination of the sciatic nerve in rats when the epineural repair was done with six sutures.

PMID: 18452111 [PubMed - indexed for MEDLINE]

48: [J Orthop Trauma](#). 2008 May-Jun;22(5):342-5.

[Related Articles,](#)
[Links](#)



Platelet gel supplementation in long bone nonunions treated by external fixation.

[Mariconda M](#), [Cozzolino F](#), [Cozzolino A](#), [D'Agostino E](#), [Bove A](#), [Milano C](#).

Federico II University, Department of Orthopaedic Surgery, Naples, Italy.
maricond@unina.it

OBJECTIVE: The aim of the present study was to evaluate the use of previously frozen, thawed platelet gel supplementation to accelerate the healing of long bone nonunions treated by external fixation. **DESIGN:** Prospective case series with historical controls. **SETTING:** University Hospital. **PATIENTS:** Twenty patients affected by tibial, humeral, or forearm atrophic nonunions were treated by percutaneous stabilization with unilateral external fixators and injection of autologous platelet gel. The healing time was compared to the result obtained in a historical control group treated without platelet gel supplementation. **MAIN OUTCOME MEASUREMENTS:** Consolidation rate and radiographic healing time of nonunions in the 2 groups were assessed by independent blinded observers. The nonunion was judged to be healed when bridging callus formation on both radiographic views was observed on at least 3 of 4 cortices. **RESULTS:** The healing rate of nonunion was 90% (18/20) in platelet gel cases and 85% (17/20) in controls, respectively (P = 0.633). The mean time until radiographic consolidation in nonunions supplemented with platelet gel (147 +/- 63 days) was not different to the result in the control group (153 +/- 61 days; P = 0.784). Analyzing the mean healing time for separate segments, no differences were noted between study and control group—that is, tibia: 112 +/- 43 and 130 +/- 5 days, respectively (P = 0.382); humerus, 225 +/- 36 and 202 +/- 70 days, respectively (P = 0.530). **CONCLUSION:** The present study failed to show the clinical usefulness of isolated

percutaneous platelet gel supplementation in long bone nonunions treated by external fixation; however, caution should be exercised in interpreting this result because the actual numbers are small and the statistical power is limited.

Publication Types:

- [Controlled Clinical Trial](#)

PMID: 18448989 [PubMed - indexed for MEDLINE]

49: [Clin Oral Implants Res.](#) 2008 Jun;19(6):539-45. Epub 2008 Apr 16.

[Related Articles,](#)
[Links](#)



Effect of platelet-rich plasma on bone regeneration in dentistry: a systematic review.

[Plachokova AS](#), [Nikolidakis D](#), [Mulder J](#), [Jansen JA](#), [Creugers NH](#).

Department of Periodontology & Biomaterials, College of Dental Sciences, Radboud University Nijmegen Medical Centre, Nijmegen, The Netherlands.

OBJECTIVE: To review systematically the reported effects of platelet-rich plasma (PRP) on bone regeneration. **MATERIAL AND METHODS:** Up to June 2006, MEDLINE and Cochrane databases were explored with different combinations of three search terms: 'PRP', 'bone regeneration', 'dentistry' and their synonyms. Inclusion criteria: human controlled clinical trials designed to treat maxillofacial bony defects with application of PRP (test) or without PRP (control), including at least five patients with a follow-up period of more than 3 months and using clinical assessment, radiography, histology and/or histomorphometry for evaluation. Literature search, selection of eligible articles and data extraction were carried out independently by two readers. **RESULTS:** The literature search revealed 108 references, of which 17 were selected for further analysis. Finally, nine articles fulfilling the inclusion criteria were selected for systematic review. Owing the substantial heterogeneity of the studies it was not possible to analyze the data statistically. An attempt was made to compare results from studies that used similar outcome measures by calculating and adding confidence intervals to the data presented in the original papers. Differences in treatment effects for periodontal defects in terms of clinical attachment level (CAL) were significant (ranging from 0.8 to 3.2 mm). The reported effects of PRP in sinus elevation (compared with their controls) were <10%. **CONCLUSION:** We found evidence for beneficial effects of PRP in the treatment of periodontal defects. Evidence for beneficial effects of PRP in sinus elevation appeared to be weak. No conclusions can be drawn about other applications of PRP in dentistry.

Publication Types:

- [Review](#)

PMID: 18422984 [PubMed - indexed for MEDLINE]

50: [J Oral Implantol.](#) 2008;34(1):25-33.

[Related Articles,](#)
[Links](#)

Analysis of a rapid, simple, and inexpensive technique used to obtain platelet-rich plasma for use in clinical practice.

[Rutkowski JL](#), [Thomas JM](#), [Bering CL](#), [Speicher JL](#), [Radio NM](#), [Smith DM](#), [Johnson DA](#).

The use of platelet-rich plasma (PRP) has become more generally accepted, and implant dentists are using PRP more frequently to promote the healing of oral surgical and/or periodontal wounds. Critical elements of PRP are thought to be growth factors contained within the concentrated platelets. These growth factors are known to promote soft-tissue healing, angiogenesis and osteogenesis. We present a rapid, simple, and inexpensive methodology for preparing PRP using the Cliniseal centrifuge method. This study demonstrates that platelets are concentrated approximately 6-fold without altering platelet morphology. Further we demonstrate that key growth factors, platelet-derived growth factor BB (PDGF-BB), transforming growth factor B (TGF-B1), vasculature endothelial growth factor (VEGF), and epidermal growth factor (EGF) are present in comparable or higher concentrations than those reported with the use of other techniques. Prolonged bench set time (>3 hours) after centrifugation resulted in decreased concentration of TGF-B1 but not decreased concentration of PDGF-BB, VEGF, or EGF. This study confirms the molecular aspects of PRP obtained using this inexpensive and efficient methodology.

Publication Types:

- [Research Support, Non-U.S. Gov't](#)

PMID: 18390240 [PubMed - indexed for MEDLINE]

51: [Transfus Apher Sci.](#) 2008 Apr;38(2):167-73. Epub 2008 Mar 17.

[Related Articles,](#)
[Links](#)



Treatment of chronic femoral osteomyelitis with platelet-rich plasma (PRP): a case report.

[Yuan T, Zhang C, Zeng B.](#)

Orthopaedic Department, Shanghai Sixth People's Hospital, Shanghai Jiaotong University, Shanghai, China.

Chronic osteomyelitis is a serious problem in developing countries. A lot of patients with chronic osteomyelitis have to be treated for a very long period and get several operations including complete debridement, antibiotic bead implant, bone grafts, etc. However, traditional methods seem to be ineffective in some patients, who always have a high incidence of recurrence. We report a case of chronic osteomyelitis in bilateral femurs, which has been treated with long time antibiotic therapy, about twenty debridements, yet the sinus remained unhealed for over four years. At the end of this period, we used PRP to treat the unhealed sinus and obtained good results. Though the mechanism by which PRP treats chronic osteomyelitis is now unclear, the results encourage study further.

Publication Types:

- [Case Reports](#)

PMID: 18343727 [PubMed - indexed for MEDLINE]

52: [Am J Sports Med.](#) 2008 Jun;36(6):1171-8. Epub 2008 Mar 7.

[Related Articles,](#)
[Links](#)



Can platelet-rich plasma enhance tendon repair? A cell culture study.

[de Mos M, van der Windt AE, Jahr H, van Schie HT, Weinans H, Verhaar JA, van](#)

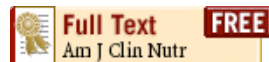Department of Orthopaedics, Erasmus MC University Medical Center, Rotterdam, the Netherlands. m.demos@erasmusmc.nl

BACKGROUND: Autologous platelet-rich plasma (PRP) application appears to improve tendon healing in traumatic tendon injuries, but basic knowledge of how PRP promotes tendon repair is needed. **HYPOTHESIS:** Platelet-rich plasma has a positive effect on cell proliferation and collagen production and induces the production of matrix-degrading enzymes and endogenous growth factors by human tenocytes. **STUDY DESIGN:** Controlled laboratory study. **METHODS:** Human tenocytes were cultured 14 days in 2% fetal calf serum medium complemented with 0%, 10%, or 20% vol/vol platelet-rich clot releasate ([PRCR] the active releasate of PRP) or platelet-poor clot releasate (PPCR). At day 4, 7, and 14, cell amount, total collagen, and gene expression of collagen I alpha 1 (COL1) and III alpha 1 (COL3), matrix metalloproteinases ([MMPs] MMP1, MMP3, and MMP13), vascular endothelial-derived growth factor (VEGF)-A, and transforming growth factor (TGF)-beta1 were analyzed. **RESULTS:** Platelet numbers in PRP increased to 2.55 times baseline. Growth-factor concentrations of VEGF and platelet-derived growth factor (PDGF)-BB were higher in PRCR than PPCR. Both PRCR and PPCR increased cell number and total collagen, whereas they decreased gene expression of COL1 and COL3 without affecting the COL3/COL1 ratio. PRCR, but not PPCR, showed upregulation of MMP1 and MMP3 expression. Matrix metalloproteinase 13 expression was not altered by either treatment. PRCR increased VEGF-A expression at all time points and TGF-beta1 expression at day 4. **CONCLUSION:** In human tenocyte cultures, PRCR, but also PPCR, stimulates cell proliferation and total collagen production. PRCR, but not PPCR, slightly increases the expression of matrix-degrading enzymes and endogenous growth factors. **CLINICAL RELEVANCE:** In vivo use of PRP, but also of PPP to a certain extent, in tendon injuries might accelerate the catabolic demarcation of traumatically injured tendon matrices and promote angiogenesis and formation of a fibrovascular callus. Whether this will also be beneficial for degenerative tendinopathies remains to be elucidated.

PMID: 18326832 [PubMed - indexed for MEDLINE]

53: [Am J Clin Nutr.](#) 2008 Feb;87(2):323-31.

[Related Articles,
Links](#)



Favorable effects of berry consumption on platelet function, blood pressure, and HDL cholesterol.

[Erlund I](#), [Koli R](#), [Alfthan G](#), [Marniemi J](#), [Puukka P](#), [Mustonen P](#), [Mattila P](#), [Jula A](#).

Biomarker Laboratory, Department of Health and Functional Capacity, National Public Health Institute, Helsinki, Finland. iris.erlund@ktl.fi

BACKGROUND: Berries are a particularly rich source of polyphenols. They also contain other bioactive substances, such as vitamin C. Previous studies indicated that the consumption of polyphenol-rich foods (eg, cocoa, tea, and red wine) may induce beneficial changes in pathways related to cardiovascular health. Whether the consumption of berries has similar effects is unknown. **OBJECTIVE:** We aimed to investigate the effects of berry consumption on hemostatic function, serum lipids, and blood pressure (BP). **DESIGN:** Middle-aged unmedicated subjects (n = 72) with cardiovascular risk factors consumed moderate amounts of berry or control products for 8 wk in a single-blind, randomized, placebo-controlled intervention trial. **RESULTS:** Berry consumption inhibited platelet function as measured with a platelet function analyzer (using collagen and ADP as platelet activator) [changes: 11% and -1.4% in the berry and control groups, respectively; P = 0.018, analysis of covariance (ANCOVA)]. Plasma biomarkers of platelet activation, coagulation, and fibrinolysis did not change during the intervention. Serum HDL-cholesterol concentrations increased significantly more (P = 0.006, ANCOVA) in the berry than in the control group (5.2% and 0.6%, respectively), but total cholesterol and triacylglycerol remained unchanged. Systolic BP decreased significantly (P = 0.050, ANCOVA); the

decrease mostly occurred in subjects with high baseline BP (7.3 mm Hg in highest tertile; $P = 0.024$, ANCOVA). Polyphenol and vitamin C concentrations in plasma increased, whereas other nutritional biomarkers (ie, folate, tocopherols, sodium, and potassium) were unaffected. **CONCLUSION:** The consumption of moderate amounts of berries resulted in favorable changes in platelet function, HDL cholesterol, and BP. The results indicate that regular consumption of berries may play a role in the prevention of cardiovascular disease.

Publication Types:

- [Randomized Controlled Trial](#)
- [Research Support, Non-U.S. Gov't](#)

PMID: 18258621 [PubMed - indexed for MEDLINE]

54: [Indian J Dent Res](#). 2008 Jan-Mar;19(1):42-6.

[Related Articles,](#)
[Links](#)



Platelet-rich fibrin: evolution of a second-generation platelet concentrate.

[Sunitha Raja V](#), [Munirathnam Naidu E](#).

Department of Periodontics, Meenakshiammal Dental College and Hospital, Maduravoyal, Chennai, India. sunitha.smiles@yahoo.com

Platelet-rich plasma (PRP) is a platelet concentrate that has been used widely to accelerate soft-tissue and hard-tissue healing. The preparation of PRP has been described by several authors. Platelet-rich fibrin (PRF) was first described by Choukroun et al. in France. It has been referred to as a second-generation platelet concentrate, which has been shown to have several advantages over traditionally prepared PRP. Its chief advantages include ease of preparation and lack of biochemical handling of blood, which makes this preparation strictly autologous. This article describes the evolution of this novel platelet concentrate, referred to as PRF.

Publication Types:

- [Review](#)

PMID: 18245923 [PubMed - indexed for MEDLINE]

55: [J Oral Implantol](#). 2007;33(6):371-82.

[Related Articles,](#)
[Links](#)

Use of platelet-rich plasma in the management of oral biphosphonate-associated osteonecrosis of the jaw: a report of 2 cases.

[Lee CY](#), [David T](#), [Nishime M](#).

CLee555294@aol.com

Bisphosphonates (BP) are nonhormonal medications used in the treatment of various bone malignancies and metabolic conditions. Since 2003, there have appeared a significant and growing number of articles in the worldwide medical and dental literature describing the complication of an osteonecrosis of the jaws associated with the intravenous and, most recently, the oral form of BP medication that has been refractory to any definitive form of treatment. The authors have successfully managed 2 patients taking the oral form of BP with adjunctive treatment using platelet-rich plasma (PRP), and in one case with hyperbaric oxygen (HBO). We were able to obtain complete remission in each case, which is defined

as resolution of pain and complete closure of exposed bone in the jaws. The purpose of this report is to describe a treatment protocol and the rationale for using PRP and HBO to obtain complete remission of this new pathologic condition.

Publication Types:

- [Case Reports](#)
- [Review](#)

PMID: 18240798 [PubMed - indexed for MEDLINE]

56: [Acta Dermatovenerol Alp Panonica Adriat.](#) 2007
Dec;16(4):156-65.

[Related Articles,](#)
[Links](#)



Use of platelet growth factors in treating wounds and soft-tissue injuries.

[Rozman P, Bolta Z.](#)

Department of Immunohematology, Blood Transfusion Centre of Slovenia, Slajmerjeva 6, SI-1000 Ljubljana, Slovenia. primoz.rozman@ztn.si

Tissue repair begins with clot formation and platelet degranulation, which release the growth factors (GFs) necessary for wound repair. Platelet-derived GFs are biologically active substances that enhance tissue repair mechanisms such as chemotaxis, cell proliferation, angiogenesis, extracellular matrix deposition, and remodeling. This review describes the biological background of the topical therapy of wounds and soft-tissue injuries with platelet gel (PG) and PG-derived GFs as well as the success of the clinical studies performed so far. Some other interesting topical applications of PG are also described. Platelet-derivatives represent a promising therapeutic modality, offering opportunities for treatment of wounds, ulcers, soft-tissue injuries, and various other applications in regenerative medicine.

Publication Types:

- [Review](#)

PMID: 18204746 [PubMed - indexed for MEDLINE]

57: [J Cell Physiol.](#) 2008 Jun;215(3):837-45.

[Related Articles,](#)
[Links](#)



Platelet-rich plasma enhances the initial mobilization of circulation-derived cells for tendon healing.

[Kajikawa Y, Morihara T, Sakamoto H, Matsuda K, Oshima Y, Yoshida A, Nagae M, Arai Y, Kawata M, Kubo T.](#)

Department of Orthopaedics, Graduate School of Medical Science, Kyoto Prefectural University of Medicine, Kyoto, Japan. kajiyoshi777@yahoo.co.jp

Circulation-derived cells play a crucial role in the healing processes of tissue. In early phases of tendon healing processes, circulation-derived cells temporarily exist in the wounded area to initiate the healing process and decrease in number with time. We assumed that a delay of time-dependent decrease in circulation-derived cells could improve the healing of tendons. In this study, we injected platelet-rich plasma (PRP) containing various kinds of growth factors into the wounded area of the patellar tendon, and compared the

effects on activation of circulation-derived cells and enhancement of tendon healing with a control group (no PRP injection). To follow the circulation-derived cells, we used a green fluorescent protein (GFP) chimeric rat expressing GFP in the circulating cells and bone marrow cells. In the PRP group, the numbers of GFP-positive cells and heat-shock protein (HSP47; collagen-specific molecular chaperone)-positive cells were significantly higher than in the control group at 3 and 7 days after injury. At the same time, the immunoreactivity for types I and III collagen was higher in the PRP group than in the control group at early phase of tendon healing. These findings suggest that locally injected PRP is useful as an activator of circulation-derived cells for enhancement of the initial tendon healing process. (c) 2008 Wiley-Liss, Inc.

Publication Types:

- [Research Support, Non-U.S. Gov't](#)

PMID: 18181148 [PubMed - indexed for MEDLINE]

58: [J Biomed Mater Res A](#). 2008 Sep 15;86(4):1128-36.

[Related Articles,
Links](#)



Controlled delivery of platelet-rich plasma-derived growth factors for bone formation.

[Lu HH](#), [Vo JM](#), [Chin HS](#), [Lin J](#), [Cozin M](#), [Tsay R](#), [Eisig S](#), [Landesberg R](#).

Biomaterials and Interface Tissue Engineering Laboratory, Department of Biomedical Engineering, Columbia University, New York, New York 10027, USA.
hl2052@columbia.edu

Platelet-rich plasma (PRP) represents an autologous source of growth factors essential for bone regeneration. The clinical efficacy of PRP is, however, unpredictable, and this is likely due to the inefficient and inconsistent delivery of PRP-derived growth factors. Previous investigations have shown that current methods of PRP preparation result in a premature release of the relevant bone stimulatory factors. As successful bone regeneration requires multiple factors presented in a physiologic temporal and spatial cascade, the objective of this study is to control the bioavailability of PRP-derived growth factors using a hydrogel carrier system. Specifically, the release of platelet-derived growth factor, transforming growth factor beta-1, and insulin-like growth factor from two types of alginate carriers was compared over time. The effects of the released factors on the growth and alkaline phosphatase (ALP) activity of human osteoblast-like cells were also evaluated. It was found that factor release profiles varied as function of carrier type, and binding of growth factors to the alginate matrix also modulated their release. The bioactivity of released factors was maintained in vitro and they promoted cell proliferation and ALP activity. These results demonstrate the potential of this autologous multifactor delivery system for controlling the bioavailability of PRP-derived factors. Future studies will focus on optimizing this system to increase the clinical efficacy of PRP by matching the distribution and temporal sequencing of PRP-derived factors to the bone healing cascade.

Publication Types:

- [Research Support, Non-U.S. Gov't](#)

PMID: 18181109 [PubMed - indexed for MEDLINE]

59: [Vox Sang](#). 2008 Apr;94(3):202-8. Epub 2008 Jan 7.

[Related Articles,
Links](#)

Platelet-rich plasma and platelet gel preparation using Plateltex.

[Mazzucco L](#), [Balbo V](#), [Cattana E](#), [Borzini P](#).

Blood Transfusion Centre and Biotechnology Laboratory, Ospedale SS Antonio e Biagio, Alessandria, Italy. lmazzucco@ospedale.al.it

BACKGROUND: The platelet gel is made by embedding concentrate platelets within a semisolid (gel) network of polymerized fibrin. It is believed that this blood component will be used more and more in the treatment of several clinical conditions and as an adjunctive material in tissue engineering. Several systems are available to produce platelet-rich plasma (PRP) for topical therapy. Recently, a new system became commercially available, Plateltex. Here we report the technical performance of this system in comparison with the performance of other commercially available systems: PRGF, PRP-Landesber, Curasan, PCCS, Harvest, Vivostat, Regen and Fibrinet. **MATERIAL AND METHODS:** Both the PRP and the gel were prepared according to the manufacturer's directions. The blood samples of 20 donors were used. The yield, the efficiency, and the amount of platelet-derived growth factor AB (PDGF-AB), transforming growth factor beta, vascular endothelial growth factor and fibroblast growth factor were measured in the resulting PRP. The feature of the batroxobin-induced gelation was evaluated. **RESULTS:** The yield, the collection efficiency and the growth factor content of Plateltex were comparable to those of most of the other available systems. The gelation time was not dependent on the fibrinogen concentration; however, it was strongly influenced by the contact surface area of the container where the clotting reaction took place ($P < 0.0001$). **CONCLUSIONS:** Plateltex provided platelet recovery, collection efficiency and PDGF-AB availability close to those provided by other systems marketed with the same intended use. Batroxobin, the enzyme provided to induce gelation, acts differently from thrombin, which is used by most other systems. Platelets treated with thrombin become activated; they release their growth factors quickly. Furthermore, thrombin-platelet interaction is a physiological mechanism that hastens the clot-retraction rate. On the contrary, platelets treated with batroxobin do not become activated; they are passively entrapped within the fibrin network, and their growth factor release occurs slowly. In these conditions, the clot retraction takes longer to occur. According to these differences between thrombin and batroxobin, it is expected that batroxobin-induced PRP activation will tailor slow release of the platelet content, thus, providing longer in loco availability of trophic factors. In selected clinical conditions, this durable anabolic factor availability might be preferable to quick thrombin-induced growth factor release.

Publication Types:

- [Comparative Study](#)
- [Evaluation Studies](#)

PMID: 18179680 [PubMed - indexed for MEDLINE]

□ **60:** [Oral Surg Oral Med Oral Pathol Oral Radiol Endod.](#)
2008 Jan;105(1):e5-e12.

[Related Articles,
Links](#)

ELSEVIER
FULL-TEXT ARTICLE

Evaluation of factors that can modify platelet-rich plasma properties.

[Andrade MG](#), [de Freitas Brandão CJ](#), [Sá CN](#), [de Bittencourt TC](#), [Sadigursky M](#).

Bahia Foundation for Science Development and Postgraduate Program in Immunology, Bahia Federal University, Bahia, Brazil. miguelsetubal@hotmail.com

OBJECTIVE: The aim of this article is to discuss a protocol for obtaining platelet-rich plasma (PRP) and evaluate which factors, derived from its preparation method and from

whole blood, modify PRP cytometry and coagulation time. **STUDY DESIGN:** Whole blood, harvested from 50 rabbits, was centrifuged at 300g for 10 minutes. Supernatant was recentrifuged at 5000g for 5 minutes. PRP was clotted with calcium chloride. Whole blood and PRP cytometry were obtained through automatic measurement. The amount of erythrocyte- and platelet-poor plasma drawn from whole blood was measured. Hematocrit, platelet and leukocyte count, mean corpuscular volume (MCV) and mean platelet volume (MPV), mean, standard deviation, and median were also calculated at whole blood and PRP. PRP coagulation time was also analyzed. Mean values between groups were analyzed using Student t test. Correlations were evaluated using Pearson's correlation coefficient. The significance level was set at $P < .05$. A linear regression was performed to investigate the relationship among the correlated variables. **RESULTS:** From whole blood, 2.68 mL of erythrocytes and 5.72 mL of platelet-poor plasma (PPP) were removed. PRP platelet count was 2,324,080 cells/microL. Whole blood hematocrit influenced the amount of cells and PPP removed, as well as PRP platelet count. PRP platelet count was dependent on whole blood hematocrit and platelet count, and does not interfere in PRP coagulation time. A linear interaction was confirmed between the variables that presented significant Pearson correlation. **CONCLUSIONS:** The protocol evaluated produces a good PRP. Whole-blood parameters can predict PRP features. Whole-blood hematocrit is an important variable for PRP preparation and PRP cytometry characterization. PRP platelet count is dependent upon whole-blood platelet count.

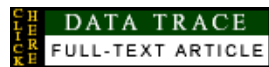Publication Types:

- [Evaluation Studies](#)
- [Research Support, Non-U.S. Gov't](#)

PMID: 18155603 [PubMed - indexed for MEDLINE]

61: [J Surg Orthop Adv](#). 2007 Winter;16(4):159-63.

[Related Articles, Links](#)



Influence of a platelet concentrate on prosthetic bone ingrowth in a rabbit model.

[Chaput CD](#), [Patel KV](#), [Brindley GW](#), [Roux MA](#), [Hu N](#), [Dmitriev A](#), [Cunningham B](#).

Department of Orthopaedics, Scott & White Hospital, 2401 South 31st Street, Temple, TX 76508, USA. cchaput@swmail.sw.org

Recent studies have shown that an increase in bone ingrowth by addition of osteogenic growth factors can reduce micro motion and gross implant motion and contribute to joint implant stability through osseointegration. Platelet-rich plasma (PRP) has the potential to provide growth factors that may be conducive to osseointegration at the bone-implant interface. This study analyzed the influence of PRP on bone ingrowth upon a beaded metal implant in distal femurs of 22 rabbits. Rabbit limbs were randomly assigned to receive an implant plus PRP or plain implant. Half of the specimens were randomly assigned to a 2-week group ($n = 20$) or a 5-week group ($n = 20$). Histologic and histomorphometric comparison between implant alone and implant plus PRP, at 2 and 5 weeks, was performed. In both the 2- and 5-week comparisons, there was no statistical difference ($p > .05$) in bone ingrowth between the control and PRP group, despite a slight increase in trabecular bone growth in PRP groups. This study suggests that PRP is not a major contributing factor to bone ingrowth at the bone-implant interface. This supports growing evidence in the literature that PRP can lead to variable bone growth stimulation in vivo.

Publication Types:

- [Comparative Study](#)

- 62: [Vox Sang.](#) 2008 Jan;94(1):64-9. Epub 2007 Nov 13.

[Related Articles,](#)
[Links](#)



Topical use of platelet-rich plasma to influence bone volume in maxillary augmentation: a prospective randomized trial.

[Schaaf H](#), [Streckbein P](#), [Lendeckel S](#), [Heidinger K](#), [Görtz B](#), [Bein G](#), [Boedecker RH](#), [Schlegel KA](#), [Howaldt HP](#).

Department of Maxillofacial Surgery, University of Giessen, Giessen, Germany.
heidrun.schaaf@chiru.med.uni-giessen.de

BACKGROUND AND OBJECTIVES: The atrophic posterior maxilla often requires restoration of the alveolar ridge due to a lack of bone quantity and quality before dental implant placement. The aim of this study was to verify the hypothesis that platelet-rich plasma (PRP) has an influence on bone density in the maxilla after sinus floor elevation in combination with autologous cancellous bone from the iliac crest. Therefore, a randomized, prospective, controlled trial was set up in two centres. **STUDY DESIGN AND METHODS:** Fifty-three patients who underwent osteoplastic bone grafting for sinus floor elevation were included. The intervention group was treated with defined concentrations of PRP in addition to transplanted bone. Bone biopsy was performed 4 months after augmentation. Bone volume was then measured using the histomorphometric parameter bone volume. **RESULTS:** The histomorphometric evaluation of the biopsies did not indicate superiority of any of the treatments in terms of bone volume. **CONCLUSION:** Topical use of PRP did not improve maxillary bone volume either clinically relevant or statistically significant compared to that in conventionally treated patients. The use of PRP to support bone regeneration cannot be recommended as a standard method for maxillary augmentation.

Publication Types:

- [Randomized Controlled Trial](#)

PMID: 18005082 [PubMed - indexed for MEDLINE]

- 63: [J Extra Corpor Technol.](#) 2007 Sep;39(3):177-82.

[Related Articles,](#)
[Links](#)

Autologous platelet gel and platelet-poor plasma reduce pain with total shoulder arthroplasty.

[Zavadil DP](#), [Satterlee CC](#), [Costigan JM](#), [Holt DW](#), [Shostrom VK](#).

Department of Surgery, Penn View Perfusion, Inc., North Kansas City Hospital, North Kansas City, Missouri 64116, USA. dozavadil@yahoo.com

The recovery of patients undergoing total shoulder arthroplasty (TSA) can be adversely affected by a number of complications. Autologous platelet gel (APG), produced by activating platelet-rich plasma (PRP), has been shown to improve hemostasis and wound healing and reduce infections in some surgical procedures. Activated platelet-poor plasma (PPP) has also been used as a hemostatic agent. This study examines the effects of APG and PPP treatment on TSA patients postoperatively. After Institutional Review Board (IRB) approval, 40 patients undergoing TSA at our institution were prospectively enrolled in our study. They were randomized into either a control (n = 20) or study (n = 20) group, with the study group receiving APG and PPP treatment. Preoperative demographic data, pre- and postoperative laboratory data, pain scores, pain medication, complications, pre- and postoperative range of motion measurements, and postoperative lengths of stay were

recorded for each group. The preoperative internal rotation index was significantly higher in the control group compared with treatment patients (4.64 +/- 4.46 vs. 1.88 +/- 2.44, $p < .05$). The percent hemoglobin retained postoperatively was higher in the treatment group at 24 (84.54 +/- 5.32 vs. 79.87 +/- 8.73) and 72 hours (87.46 +/- 16.03 vs. 76.70 vs. 5.96), but neither difference reached statistical significance. The treatment group had significantly lower pain scores ($p = .007$) and total fentanyl requirements ($p < .05$) compared with control patients. The internal rotation index improvement factor (postoperative internal rotation index/preoperative internal rotation index) was significantly higher in the treatment group vs. the control group ($p < .05$). Although it did not reach statistical significance, the treatment group was discharged almost 9 hours earlier than the control group (64.44 +/- 15.23 vs. 73.39 +/- 15.37). APG and PPP treatment decreased pain and provided a greater increase in internal rotation measurements postoperatively.

Publication Types:

- [Randomized Controlled Trial](#)

PMID: 17972452 [PubMed - indexed for MEDLINE]

64: [J Biomed Mater Res A](#). 2008 Jun 15;85(4):1129-34.

[Related Articles,](#)
[Links](#)



Imaging of blood plasma coagulation and its propagation at surfaces.

[Faxälv L](#), [Tengvall P](#), [Lindahl TL](#).

Department of Clinical Chemistry, Laboratory Medicine, University Hospital, SE-581 85 Linköping, Sweden. lars.faxalv@ibk.liu.se

A new method utilizing image capture and processing was developed for the analysis of blood plasma coagulation at surfaces. The coagulation was detected in a cuvette by time-lapse image capture of light scattering from the developing fibrin network. By image processing and computer analysis of the captured image data, both early detection of coagulation at the surface and the propagation phase of coagulation could be measured in the same experiment. It is possible to use both platelet-rich plasma (PRP) and platelet-free plasma (PFP) with the method, and thereby study the platelet contribution to both surface coagulation and propagation of coagulation. Two well-known model surfaces, hydrophilic and hydrophobic glass, were used in combination with PRP and PFP to illustrate the method. Hydrophilic glass activated coagulation significantly faster (PRP: 7.0 +/- 1.7 min, PFP: 5.9 +/- 1.2 min, $n = 16$) than hydrophobic glass (PRP: 50 +/- 14 min, PFP: 65 +/- 32 min, $n = 16$) in both PRP and PFP. Hydrophilic surfaces showed a faster initial propagation of coagulation adjacent to the surface (mean velocity: 0.14 +/- 0.05 mm/minute) compared with the propagation observed further out from the surface (mean velocity: 0.05 +/- 0.01 mm/min). The method is very flexible and can be suitable for screening hemocompatibility of biomaterials.

Publication Types:

- [Research Support, Non-U.S. Gov't](#)

PMID: 17907239 [PubMed - indexed for MEDLINE]

65: [Ortop Traumatol Rehabil](#). 2007 May-Jun;9(3):227-38.

[Related Articles,](#)
[Links](#)



Current opinion about using the platelet-rich gel in orthopaedics and

trauma surgery.

[Article in English, Polish]

[Wrotniak M](#), [Bielecki T](#), [Gaździk TS](#).

Katedra i Oddział Kliniczny Ortopedii Śląskiej Akademii Medycznej w Katowicach, WSS Nr 5, Sosnowiec.

The use of growth factors in combination with tissue engineering seems to be the most promising method in the future for the treatment of tissue, bone and cartilage defect. Growth factors are cytokines with regulatory functions for healing in tissues of the musculoskeletal system. These small peptides are synthesised by resident cells at the site of injury such as mesenchymal stem cells and chondrocytes, or by the infiltrating inflammatory process. Platelet-rich plasma (PRP) is a novel osteoinductive therapeutic approach that is increasingly used in treatment of such complications of bone healing processes. The activator for PRP is a mixture of thrombin and calcium chloride. After connecting these substances platelet-rich gel (PRG) is formed and numerous regulatory molecules to the injury site such as PDGF, TGF-, VEGF, IGF, EGF and antimicrobial proteins are released. The aim of this article is presentation of present knowledge about properties and possibilities of using platelet-rich plasma in the treatment of soft tissue and bone healing disturbances.

Publication Types:

- [Review](#)

PMID: 17721419 [PubMed - indexed for MEDLINE]

66: [Perfusion](#). 2007 Jan;22(1):41-50.

[Related Articles,
Links](#)



Quality assessment of platelet rich plasma during anti-platelet therapy.

[Smith CW](#), [Binford RS](#), [Holt DW](#), [Webb DP](#).

Tennessee Perfusion Services, PLLC, Centennial Medical Center, Cardiothoracic Surgery, Nashville, Tennessee 37027, USA Chadsmail@comcast.net

Platelet rich plasma (PRP) is being used with increased frequency in many surgical procedures for its known benefits of accelerated surgical wound site healing. Speculations in its efficacy in the presence of anti-platelet therapy have been proposed. To aid in defining a quality platelet rich plasma product in the presence of acetylsalicylic acid (ASA) and Plavix (clopidogrel bisulfate), we investigated three (3) groups (n = 18) of cardiac surgical patients receiving PRP. Platelet function test, platelet concentration, and quantification of growth factors (PDGF-bb and TGF-b1) were evaluated. Results showed no statistical evidence of decreased growth factors delivered to the surgical wound site in the presence of acetylsalicylic acid (ASA) and/or Plavix (clopidogrel bisulfate). Evidence in this pilot study supports the use of PRP for patients receiving Plavix and aspirin therapy without compromising the quantity of specific growth factors delivered to a wound site.

Publication Types:

- [Clinical Trial](#)
- [Research Support, Non-U.S. Gov't](#)

PMID: 17633134 [PubMed - indexed for MEDLINE]



Platelet-rich plasma stimulates osteoblastic differentiation in the presence of BMPs.

[Tomoyasu A](#), [Higashio K](#), [Kanomata K](#), [Goto M](#), [Kodaira K](#), [Serizawa H](#), [Suda T](#), [Nakamura A](#), [Nojima J](#), [Fukuda T](#), [Katagiri T](#).

Division of Pathophysiology, Research Center for Genomic Medicine, Saitama Medical University, 1397-1 Yamane, Hidaka-shi, Saitama 350-1241, Japan.

Platelet-rich plasma (PRP) is clinically used as an autologous blood product to stimulate bone formation in vivo. In the present study, we examined the effects of PRP on proliferation and osteoblast differentiation in vitro in the presence of bone morphogenetic proteins (BMPs). PRP and its soluble fraction stimulated osteoblastic differentiation of myoblasts and osteoblastic cells in the presence of BMP-2, BMP-4, BMP-6 or BMP-7. The soluble PRP fraction stimulated osteoblastic differentiation in 3D cultures using scaffolds made of collagen or hydroxyapatite. Moreover, heparin-binding fractions obtained from serum also stimulated osteoblastic differentiation in the presence of BMP-4. These results suggested that platelets contain not only growth factors for proliferation but also novel potentiator(s) for BMP-dependent osteoblastic differentiation.

Publication Types:

- [Research Support, Non-U.S. Gov't](#)

PMID: 17632078 [PubMed - indexed for MEDLINE]

Platelet-enriched fibrin glue and platelet-rich plasma in the repair of bone defects adjacent to titanium dental implants.

[You TM](#), [Choi BH](#), [Zhu SJ](#), [Jung JH](#), [Lee SH](#), [Huh JY](#), [Lee HJ](#), [Li J](#).

Graduate Student, Department of Oral & Maxillofacial Surgery, College of Dentistry, Yonsei University, Seoul, South Korea.

PURPOSE: The aim of this study was to compare the effects of platelet-enriched fibrin glue and platelet-rich plasma (PRP) on the repair of bone defects adjacent to titanium dental implants. **MATERIALS AND METHODS:** In 6 mongrel dogs, 3 screw-shaped titanium dental implants per dog were placed into the osteotomy sites in the tibia. Before implantation, a standardized gap (2.0 mm) was created between the implant surface and the surrounding bone walls. Six gaps were left empty (control group), 6 gaps were filled with autogenous particulate bone mixed with PRP (PRP group), and 6 gaps were filled with autogenous particulate bone mixed with platelet-enriched fibrin glue (fibrin glue group). **RESULTS:** After 6 weeks, the bone-implant contact was 59.7% in the fibrin glue group, 29.2% in the PRP group, and 10.2% in the control defects; this difference was statistically significant ($P < .05$). **DISCUSSION AND CONCLUSION:** Greater bone-implant contact was achieved with platelet-enriched fibrin glue than with PRP. The results indicate that platelet-enriched fibrin glue can induce a stronger peri-implant bone reaction than PRP in the treatment of bone defects adjacent to titanium dental implants.

Publication Types:

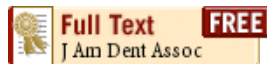- [Comparative Study](#)

- [Research Support, Non-U.S. Gov't](#)

PMID: 17622008 [PubMed - indexed for MEDLINE]

69: [J Am Dent Assoc.](#) 2007 Jul;138(7):971-7.

[Related Articles,](#)
[Links](#)



The treatment of bisphosphonate-associated osteonecrosis of the jaws with bone resection and autologous platelet-derived growth factors.

[Adornato MC](#), [Morcos I](#), [Rozanski J](#).

Faxton-St. Luke's Healthcare Dental Service, New Hartford, NY, USA.
madornato@aol.com

BACKGROUND: Bisphosphonates administered intravenously are used to treat patients with cancer who have hypercalcemia associated with malignant disease, multiple myeloma or metastatic tumors (breast, lung, prostate) in the bones. Bisphosphonates are bone resorption inhibitors and have been associated with osteonecrosis of the jaws. In this article, the authors provide an alternative treatment modality for refractory bisphosphonate-associated osteonecrosis (BON). **CASE DESCRIPTION:** The authors treated 12 patients with refractory BON and a history of long-term bisphosphonate therapy. Each patient had mucosal ulceration with exposed necrotic bone. The treatment combined bone resection with platelet-derived growth factors (PDGFs). The surgical intervention they used was a marginal resection limited to the alveolar bone. Ten of the patients recovered with complete mucosal and bone healing. **CONCLUSION:** BON has been shown to be refractory to antibiotics, minor local débridement and 0.12 percent chlorhexidine oral rinse. Treatment of refractory BON with a combination of marginal resection and PDGF has shown favorable results, including complete wound healing in most patients. This modality has been shown to be effective in treating BON and may be a useful alternative to existing treatment strategies.

Publication Types:

- [Case Reports](#)

PMID: 17606496 [PubMed - indexed for MEDLINE]

70: [Tissue Eng.](#) 2007 Jan;13(1):147-58.

[Related Articles,](#)
[Links](#)

Mary Ann Liebert,

Intervertebral disc regeneration using platelet-rich plasma and biodegradable gelatin hydrogel microspheres.

[Nagae M](#), [Ikeda T](#), [Mikami Y](#), [Hase H](#), [Ozawa H](#), [Matsuda K](#), [Sakamoto H](#), [Tabata Y](#), [Kawata M](#), [Kubo T](#).

Department of Orthopaedics, Graduate School of Medical Science, Kyoto Prefectural University of Medicine, Kyoto, Japan.

This study evaluated the regenerative effects of platelet-rich plasma (PRP) for the degenerated intervertebral disc (IVD) in vivo. After induction of IVD degeneration in rabbits, we prepared PRP by centrifuging blood obtained from these rabbits. These PRP were injected into the nucleus pulposus (NP) of the degenerated IVDs after impregnation into gelatin hydrogel microspheres that can immobilize PRP growth factors physiochemically and release them in a sustained manner with the degradation of the

microspheres. As controls, microspheres impregnated with phosphate-buffered saline (PBS) and PRP without microspheres were similarly injected. Histologically, notable progress in IVD degeneration with time courses was observed in the PBS control, PRP-only, and sham groups. In contrast, progress was remarkably suppressed over the 8-week period in the PRP group. Moreover, in immunohistochemistry, intense immunostaining for proteoglycan in the NP and inner layer of the annulus fibrosus was observed 8 weeks after administration of PRP-impregnated microspheres. Almost all microspheres were indistinct 8 weeks after the injection, and there were no apparent side effects in this study. Our results suggest that the combined administration of PRP and gelatin hydrogel microspheres into the IVD may be a promising therapeutic modality for IVD degeneration.

Publication Types:

- [Research Support, Non-U.S. Gov't](#)

PMID: 17518588 [PubMed - indexed for MEDLINE]

71: [Haematologica](#). 2007 May;92(5):694-7.

[Related Articles](#),
[Links](#)



Platelet aggregation studies: autologous platelet-poor plasma inhibits platelet aggregation when added to platelet-rich plasma to normalize platelet count.

[Cattaneo M](#), [Lecchi A](#), [Zighetti ML](#), [Lussana F](#).

Unità di Ematologia e Trombosi, Ospedale San Paolo, DMCO Università di Milan, Milan, Italy. marco.cattaneo@unimi.it

Adjusting platelet count (PC) in platelet-rich plasma (PRP) using platelet-poor plasma (PPP) is recommended for platelet aggregation (PA) studies, but it could also affect PA independently of the decrease in PC. Analysis of aggregation tracings from healthy controls showed that PC correlated with PA in 47 diluted-PRPs, but not in 104 undiluted-PRPs. Dilution of 9 PRPs with PPP progressively decreased PA, while dilution of washed platelets with buffer hardly affected PA. Apyrase partially prevented the inhibitory effect of PPP. Therefore, the practice of diluting PRP with PPP to adjust platelet count should be avoided because it artefactually inhibits PA.

PMID: 17488697 [PubMed - indexed for MEDLINE]

72: [J Extra Corpor Technol](#). 2007 Mar;39(1):31-8.

[Related Articles](#),
[Links](#)

Autologous platelet gel in coronary artery bypass grafting: effects on surgical wound healing.

[Vang SN](#), [Brady CP](#), [Christensen KA](#), [Allen KR](#), [Anderson JE](#), [Isler JR](#), [Holt DW](#), [Smith LM](#).

Department of Perfusion Services, Mercy Medical Center, Sioux City, Iowa, USA. vangs@merchealth.com

Stimulating the body's natural healing at the cellular level can be achieved through the application of growth factors located within platelets. Once combined with a mixture of calcium and thrombin, this substance, now referred to as autologous platelet gel (APG), can be applied to surgical wound sites for patients undergoing cardiac surgery. The purpose of this study was to examine the effects of APG on surgical site infection, post-operative pain, blood loss, and bruising. After 30 mL platelet-rich plasma (PRP) was processed, 10 mL PRP was distributed on the sternum after re-approximation and 7 mL PRP before skin

closure. Ten milliliters PRP was used on the endoscopic leg harvest (EVH) site. The remaining 3 mL was sent to the laboratory for hematologic testing. Both the control (CTR) and treatment (TRT) groups were well matched, with the exception of ejection fraction and pre-operative platelet count, which was significantly higher in the TRT group. Average platelet count yield was $4.2 \pm 0.5 \times 10^3/\text{mL}$, white blood count (WBC) yielded $1.9 \pm 0.7 \times 10^3/\text{mL}$, and fibrinogen yielded $1.2 \pm 0.2 \text{ mg/dL}$ above baseline. There were no deep or superficial sternal infections. However, one patient from each group did experience a leg infection at the EVH site, which occurred after hospital discharge. More patients in the TRT group experienced less pain on postoperative day (POD) 1 and at the post-operative office follow-up. Blood loss and bruising was less in the TRT group on POD 2; however, there was no statistical significance. The application of APG seems to confer beneficial effects on pain, blood loss, and bruising. However, further studies with a greater sample size are needed to power significant differences.

Publication Types:

- [Research Support, Non-U.S. Gov't](#)

PMID: 17486871 [PubMed - indexed for MEDLINE]

73: [Ophthalmic Res.](#) 2007;39(3):124-9. Epub 2007 Mar 19.

[Related Articles,
Links](#)

KARGER Full Text

Symptomatic dry eye treatment with autologous platelet-rich plasma.

[Alio JL](#), [Colecha JR](#), [Pastor S](#), [Rodriguez A](#), [Artola A](#).

Corneal and Refractive Surgery Department, Instituto Oftalmologico de Alicante (Vissum), Alicante, Spain. rdioa@vissum.com

BACKGROUND: Autologous platelet-rich plasma (PRP) has been proven to be very effective on tissue regeneration and wound healing. Here we investigate the potential use of PRP in the treatment of symptomatic dry eye. **METHODS:** Eighteen consecutive patients with symptomatic dry eye were treated with topical PRP and followed up for 1 month. Disappearance of subjective symptoms, increase in best corrected visual acuity, tear meniscus, tear breakup time, decrease in inflammation, fluorescein staining and improvement in impression cytology were measured. **RESULTS:** Symptoms improved significantly in 89% of the patients, 28% improved at least 1 line of best corrected visual acuity. A significant improvement on lachrymal meniscus and conjunctival hyperemia and a decrease or disappearance of corneal fluorescein staining were observed. Impression cytology revealed a significant increase in conjunctival goblet cells. **CONCLUSION:** Treatment of patients suffering from significant dry eye symptoms with autologous RPR proved to be very effective, improving both patient symptoms and major clinical signs.

Publication Types:

- [Clinical Trial](#)

PMID: 17374962 [PubMed - indexed for MEDLINE]

74: [Foot Ankle Clin.](#) 2007 Mar;12(1):75-106.

[Related Articles,
Links](#)

Bioadjuvants for complex ankle and hindfoot reconstruction.

[Liporace FA](#), [Bibbo C](#), [Azad V](#), [Koerner J](#), [Lin SS](#).

Department of Orthopaedic Surgery, Trauma Division, New Jersey Medical School-

Many reconstructive options exist for symptomatic hindfoot and ankle problems. Hindfoot and tibiotalar fusions are reliable procedures with consistent results. Unfortunately, many potential complications have been cited throughout the literature. Although the most important aspect in any fusion surgery is meticulous technique, advances in technology, including PRP, bone stimulators, and BMPs seem to be useful additions in the quest to achieve solid fusions with decreased complications.

Publication Types:

- [Case Reports](#)
- [Review](#)

PMID: 17350512 [PubMed - indexed for MEDLINE]

75: [J Thromb Haemost](#). 2007 Jan;5(1):82-90.

[Related Articles, Links](#)



Normalization of platelet reactivity in clopidogrel-treated subjects.

[Vilahur G](#), [Choi BG](#), [Zafar MU](#), [Viles-Gonzalez JF](#), [Vorchheimer DA](#), [Fuster V](#), [Badimon JJ](#).

Cardiovascular Biology Research Laboratory, Mount Sinai School of Medicine, New York, NY 10029, USA.

BACKGROUND: Aspirin (ASA) + clopidogrel are commonly used in acute coronary syndrome (ACS), but persistent antiplatelet effects may complicate surgery. **METHODS AND RESULTS:** To study the possibility of normalizing platelet reactivity after ASA + clopidogrel treatment, 11 healthy subjects received a 325-mg ASA + clopidogrel loading dose (300 or 600 mg dependent on study arm), followed by 81 mg of ASA + 75 mg of clopidogrel daily for 2 days. Platelet reactivity was assessed by light transmittance aggregometry (LTA) [challenged by adenosine diphosphate (ADP), arachidonic acid (AA), collagen, and thrombin receptor activating peptide (TRAP)] and flow cytometry for platelet activation by GPIIb/IIIa receptor exposure pretreatment, 4 and 72 h postload. To normalize platelet reactivity, increasing amounts of pooled platelets from five untreated volunteers [volunteers (V)-platelet-rich plasma (PRP)] were added ex vivo to the subject's PRP (S-PRP). At both 4 and 72 h, 40% and 50% V-PRP were needed to overcome platelet disaggregation in the 300 or 600 mg arms, respectively, after ADP challenge; an additional 10% V-PRP fully normalized aggregation. Recovery of function was linear with each incremental increase of V-PRP. ADP-induced GPIIb/IIIa activation showed the same pattern as LTA ($r = 0.74$). Forty percent V-PRP was required to normalize platelet function to AA, collagen, and TRAP. **CONCLUSION:** Our results suggest that the pre-operative transfusion of 10 platelet concentrate units (the equivalent of 40% V-PRP) after a 300-mg clopidogrel loading or 12.5 units (50% V-PRP) after a 600 mg loading may adequately reverse clopidogrel-induced platelet disaggregation to facilitate postoperative hemostasis. An additional 2.5 units fully normalized platelet function. The potential clinical implications of our observations could include shorter hospitalizations and reduced bleeding complications. But these observations should be fully explored in an in vivo clinical setting with clopidogrel-treated patients before and after surgery.

Publication Types:

- [Randomized Controlled Trial](#)
- [Research Support, Non-U.S. Gov't](#)

76: [Clin Oral Implants Res](#). 2007 Feb;18(1):133-9.

[Related Articles,](#)
[Links](#)



Influence of the application of platelet-enriched plasma in oral mucosal wound healing.

[Lindeboom JA](#), [Mathura KR](#), [Aartman IH](#), [Kroon FH](#), [Milstein DM](#), [Ince C](#).

Department of Physiology, Academic Medical Center, Academic Center for Dentistry Amsterdam (ACTA), University of Amsterdam, Amsterdam, The Netherlands.
j.a.lindeboom@amc.uva.nl

PURPOSE: The aim of this study was to describe and quantify the therapeutic value of platelet concentrate on the capillary density in oral mucosal wound healing. **MATERIAL AND METHODS:** The subjects included 10 healthy edentulous patients who underwent bilaterally a sinus floor elevation procedure and a buccal onlay graft with autologous iliac crest bone for maxillary reconstruction. During surgery, platelet-rich plasma (PRP) was prepared from a blood sample taken from the patient. After randomization in a split-mouth design, at one side PRP was administered in the wound and at the contralateral side a placebo. At baseline, microvascular capillary density was scored with the orthogonal polarization spectral (OPS) imaging technique and repeated measurements were performed postoperatively on a daily basis until the tenth day, after which measurements were continued weekly until the fifth postoperative week. **RESULTS:** Ten patients, five males and five females, were included in the study with a mean age of 54.2+/-9.1 years for females and 57.6+/-6.9 years for males. Donor platelet counts from whole blood had a mean value of 248.5+/-13.5 x 10(9)/l, while the value of platelet counts in the PRP had a mean of 975.9+/-97.9 x 10(9)/l. Wound healing was significantly accelerated in the PRP-treated mucosal wounds during the first 10 postoperative days. After the second week, no obvious differences between the PRP or placebo side could be noted. **CONCLUSION:** PRP has a strong stimulant effect on capillary regeneration in wound healing. These effects are mainly noticeable during the early stages of wound healing.

Publication Types:

- [Comparative Study](#)
- [Randomized Controlled Trial](#)

PMID: 17224034 [PubMed - indexed for MEDLINE]

Items 1 - 76 of 76

One page.

Display Show Sort By Send to

[Write to the Help Desk](#)
[NCBI](#) | [NLM](#) | [NIH](#)
[Department of Health & Human Services](#)
[Privacy Statement](#) | [Freedom of Information Act](#) | [Disclaimer](#)